

# Autogenous Bone Grafting in the Anterior Maxilla for Implant Placement

Dr. Elija Bajagain,<sup>1</sup> Dr. Sajeev Shrestha,<sup>1</sup> Dr. Nabin Thapa<sup>2</sup>

<sup>1</sup>Department of Periodontology and Oral Implantology, B. P. Koirala Institute of Health Sciences, Dharan, Sunsari, Nepal;

<sup>2</sup>Province Hospital, Gorkha Bazaar, Gorkha, Nepal.

## ABSTRACT

Congenitally missing canines are rare clinical findings with significant functional and aesthetic challenges. This case report describes the comprehensive management of a 23-year-old female patient presenting with bilateral maxillary canines and left lateral incisor agenesis, retained deciduous teeth, and missing mandibular first molars. Treatment included a staged approach involving autogenous bone grafting from the mandibular symphysis, extraction of retained deciduous lateral incisor and subsequent implant placement in relation to 23 leading to successful functional and aesthetic rehabilitation.

**Keywords:** Anterior maxillary defect; autogenous bone graft; implant; ridge augmentation.

## INTRODUCTION

Congenital absence of maxillary canines is rare but has significant aesthetic and occlusal implications.<sup>1</sup> Retained deciduous teeth often complicate implant placement due to reduced alveolar bone volume.<sup>2</sup> Autogenous bone grafts remain the gold standard for ridge augmentation owing to their osteogenic, osteoinductive, and osteoconductive potential. The mandibular symphysis provides a favourable donor site because of its intramembranous nature, accessibility, and minimal post-operative morbidity.<sup>3</sup> This report presents management of anterior maxillary ridge deficiency in a young adult using symphyseal block graft followed by implant placement and prosthetic rehabilitation.

## CASE REPORT

A 23-year-old female reported with missing upper front teeth. Medical and family histories were not

significant. Dental history revealed persistent primary teeth with no eruption of permanent successors. Intraoral examination revealed missing maxillary left lateral incisor and canine, missing right canine, missing mandibular first molars, retained deciduous lateral incisor, and retained deciduous canine on the right with a midline diastema. Radiographs and cone beam computed tomography (CBCT) confirmed agenesis of 13, 22, and 23 (teeth numbered according to two-digit tooth numbering system) with insufficient alveolar bone width on the left (Figure 1).

The patient desired early replacement of missing teeth. Orthodontic alignment was confined to anterior maxilla to close the diastema and preserve implant spaces. The treatment plan involved extraction of retained teeth, immediate implant placement at site 13, delayed implant placement on mandibular first molars, and ridge augmentation at site 23 with an autogenous symphyseal block graft, followed by implant placement and prosthetic restoration.

Routine preoperative antisepsis was performed. Under local anaesthesia (2% lidocaine with 1:200,000 adrenaline), intrasulcular incision from 21-23 with two vertical releasing incisions were given to reflect a full-thickness flap. An intrasulcular incision from 42-33 with a vertical releasing incision distal to 33 was made to raise a flap over the symphysis (Figure

## Correspondence

Dr. Elija Bajagain

Email: elijabajagain@gmail.com



## Citation

Bajagain E, Shrestha S, Thapa N. Autogenous Bone Grafting in the Anterior Maxilla for Implant Placement. J Nepal Soc Perio Oral Implantol. 2025 Jan-Jun;9(17):45-9.

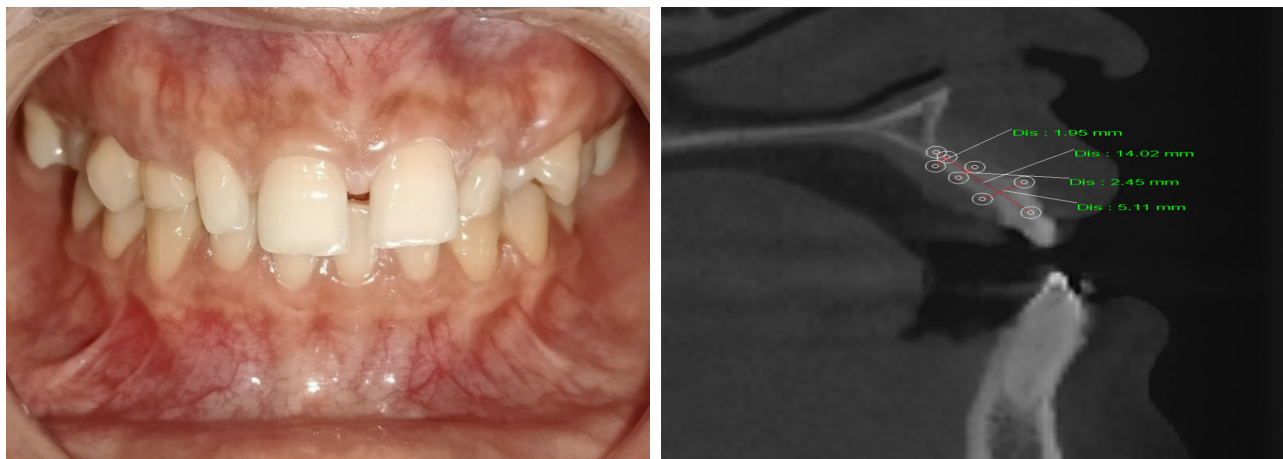


Figure 1 (a, b): Preoperative clinical photograph showing frontal view and CBCT scan showing the ridge dimension bucco-lingually with respect to 22, 23.

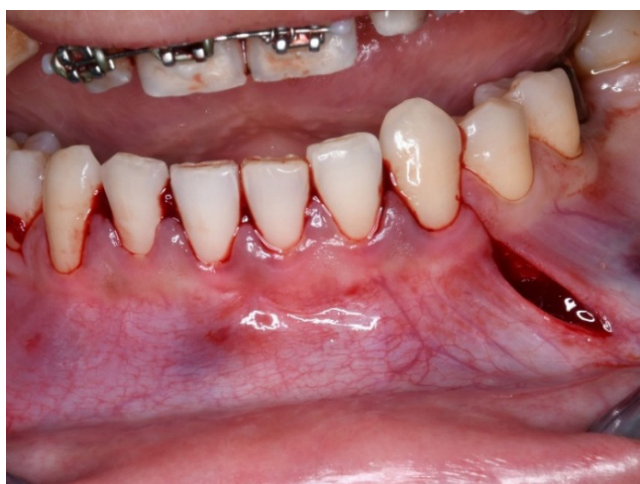

Figure 2: Horizontal and vertical incisions given at the donor site.

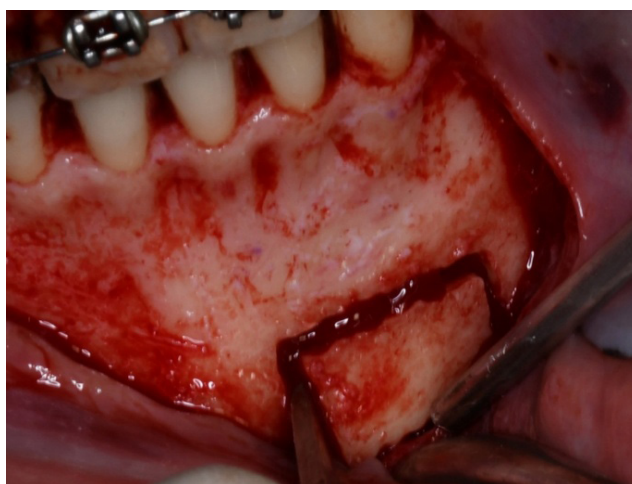


Figure 3: Graft obtained after horizontal and vertical cuts and use of mallet to procure the graft.

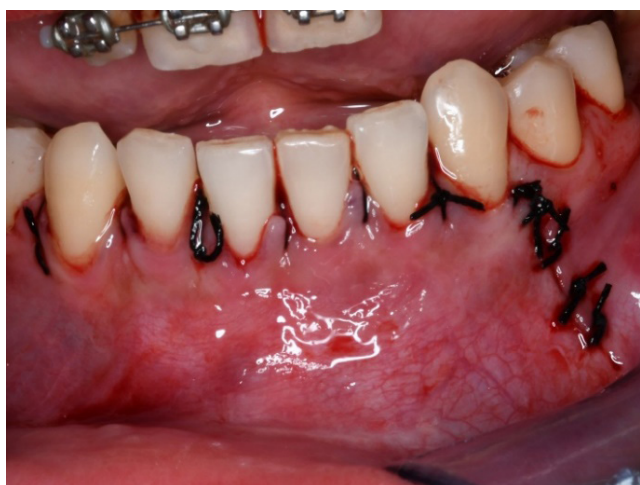

Figure 4: Primary closure obtained at the donor site.

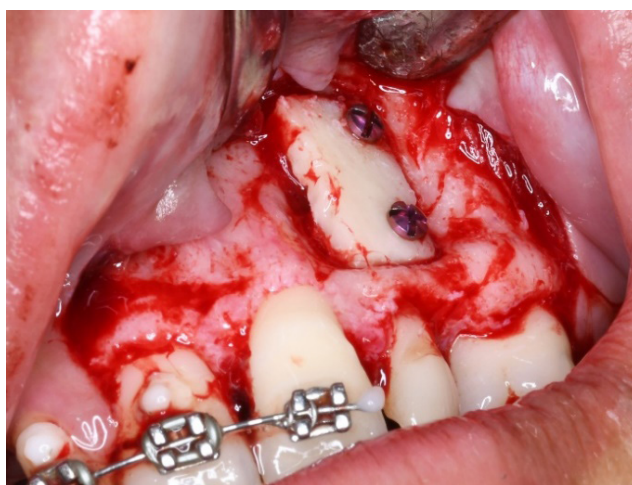


Figure 5: Bone graft adapted to the recipient site with screws.

2). The graft outline was marked 5 mm away from the mental foramen, tooth apices, and inferior border. Using a round bur and surgical-length 701 bur, osteotomy was extended into marrow space, and the block graft was gently separated with an Ochsenbein chisel and mallet (Figure 3). The donor site edges were smoothed, covered with a resorbable membrane, and sutured primarily (Figure 4).

The block graft was adapted to the maxillary defect and fixed using two 1.5 mm titanium screws (Figure 5). Cancellous bone chips from the donor site filled gaps around the block. After periosteal release, the flap was closed tension-free and sutured (Figure 6).

The patient was prescribed Amoxicillin with Clavulanic acid 625 mg three times a day (TDS) for seven days, Metronidazole 400 mg TDS for seven days, Paracetamol with Ibuprofen as needed, and 0.2% Chlorhexidine mouth rinse for two weeks. A single intramuscular injection of Dexamethasone 8 mg was administered. Healing was uneventful. After

six months, CBCT revealed adequate ridge width (Figure 7).

After six months, under local anaesthesia, a flap was raised around 21-23, and the retained deciduous lateral incisor was extracted. Fixation screws were removed, and sequential osteotomy was performed. A 3.5 × 11.5 mm i-Fix® implant was placed at site 23 with 40 Ncm insertion torque, indicating good primary stability (Figure 8). Antibiotics and analgesics were continued post-operatively.

After four months, customised provisional crowns were delivered to contour the soft tissue. At eight months, satisfactory gingival architecture was achieved. A closed-tray final impression using putty and light body silicone was made, and a screw-retained zirconia crown was delivered at site 23 (Figure 9). At twelve months' follow-up, peri-implant tissues were healthy, radiographs showed stable crestal bone, and the patient was satisfied functionally and aesthetically.

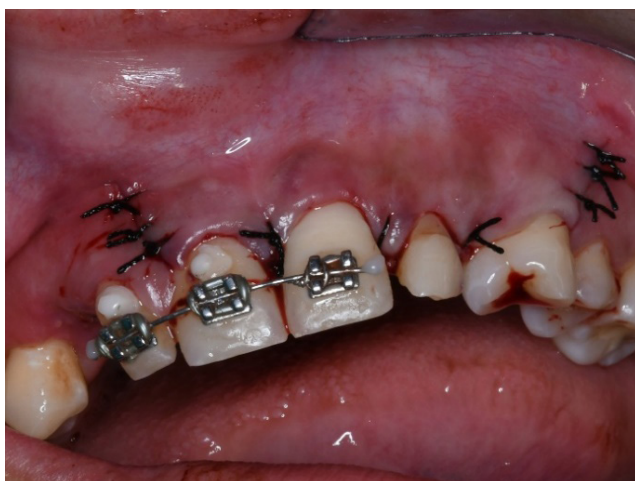

Figure 6: Sutures placed at the recipient site.

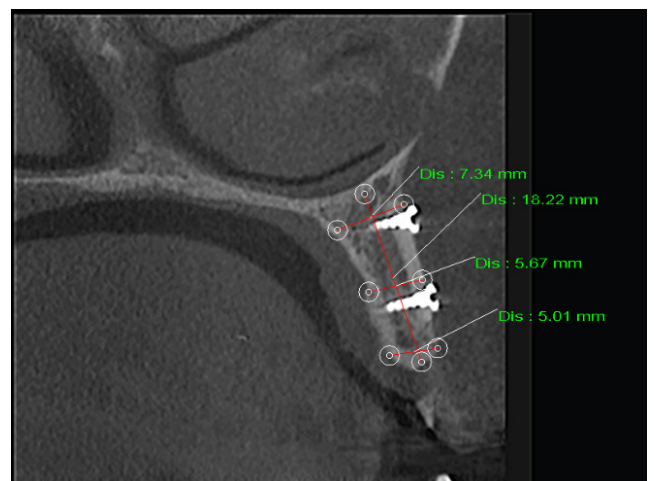


Figure 7: Adequate buccolingual width obtained after autograft with respect to 22, 23.

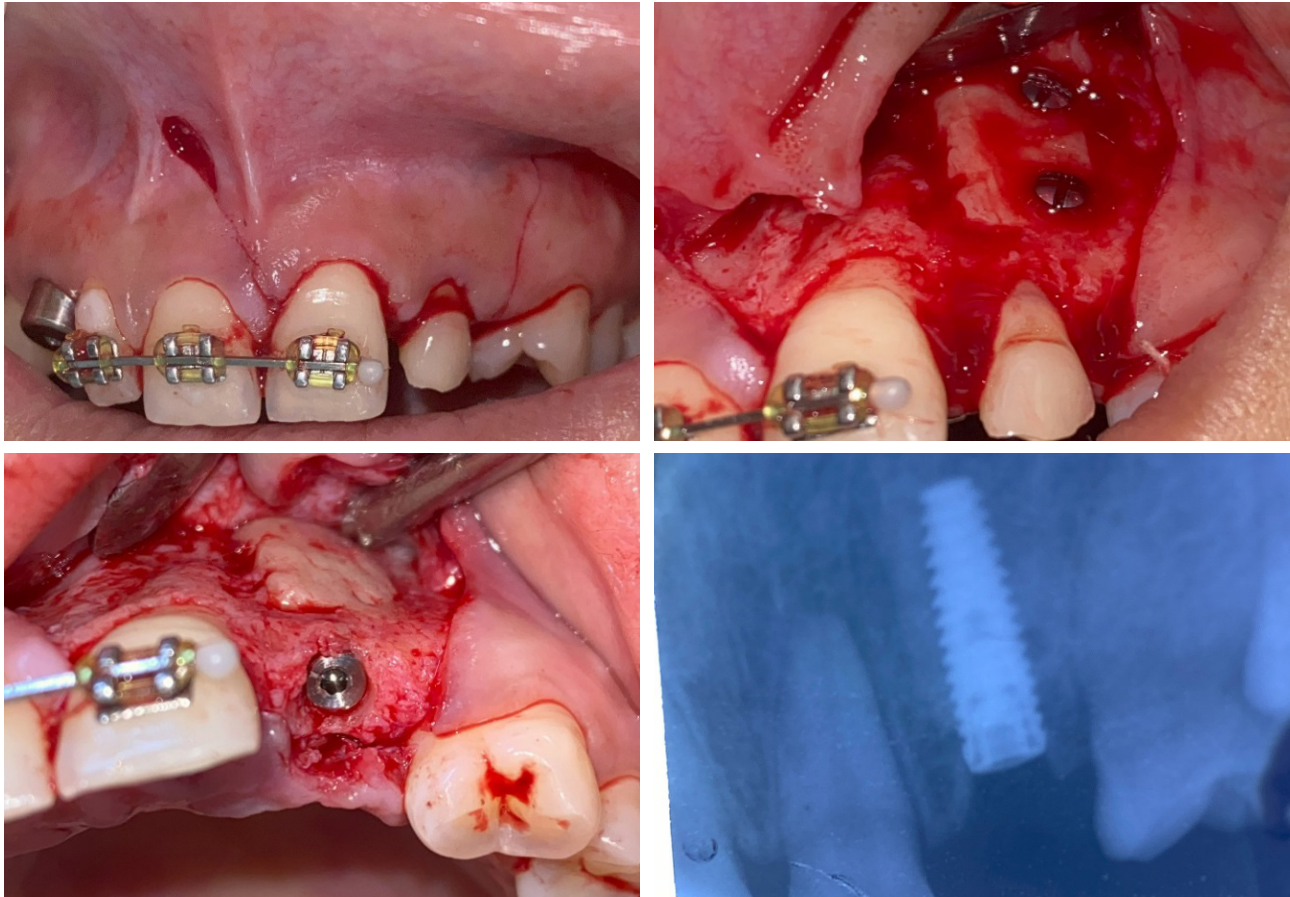


Figure 8 (a, b, c, d): Flap raised to extract deciduous tooth followed by implant placement.

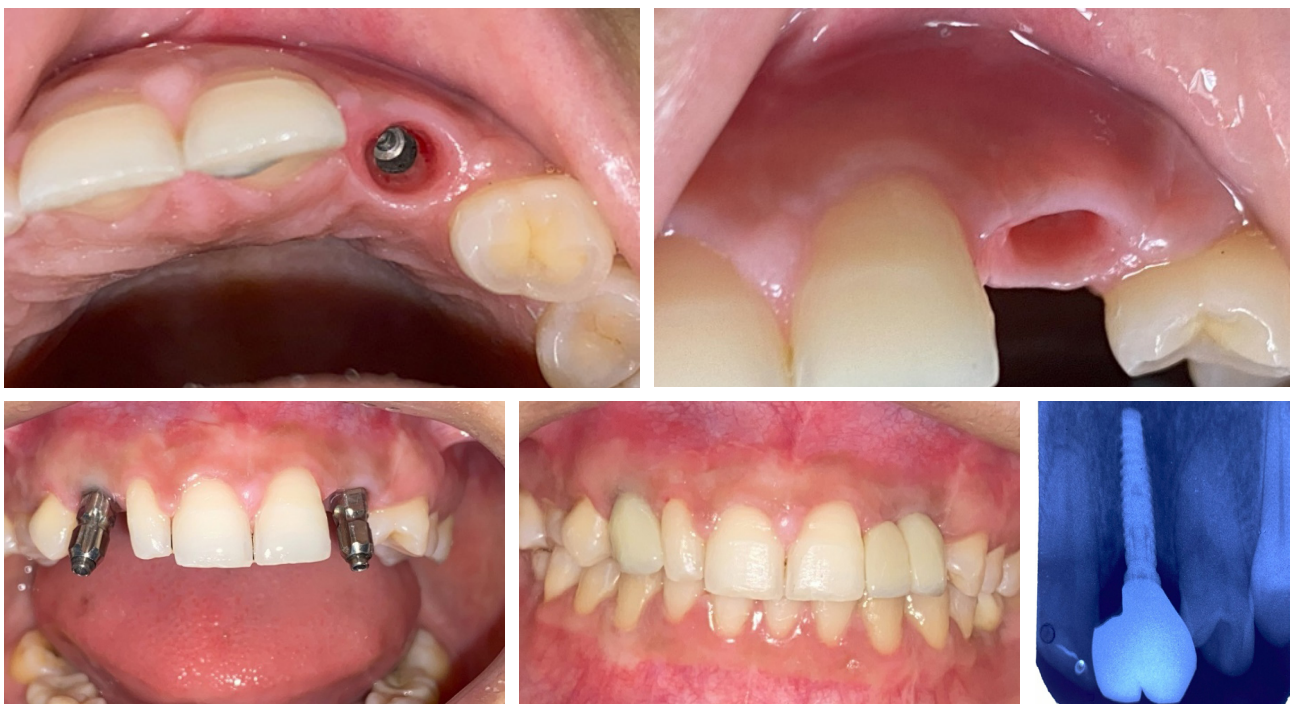

Figure 9 (a, b, c, d, e): Final prosthesis delivery.

## DISCUSSION

Congenital absence of maxillary canines is rare compared to lateral incisor agenesis yet it has significant aesthetic and functional implications.<sup>1,4</sup> In such cases, alveolar bone development is compromised due to absence of eruptive stimulation, often resulting in narrow ridge. Ridge deficiency in congenitally missing teeth often necessitates augmentation for implant placement.

Various techniques such as guided bone regeneration (GBR), particulate grafting, and ridge splitting have been proposed, but autogenous block grafts remain the gold standard for horizontal deficiencies because of their structural stability and predictable integration. Autogenous grafts possess osteogenic, osteoinductive, and osteoconductive properties, supporting rapid vascularisation and new bone formation.<sup>5-7</sup>

The mandibular symphysis offers an ideal intraoral donor site due to intramembranous origin, accessibility, and low morbidity.<sup>8</sup> In the present case, a mandibular symphyseal block graft was selected over guided bone regeneration (GBR) due to the

defect's horizontal deficiency and a need for stable graft volume. Autogenous bone grafts achieve more consistent horizontal augmentation (>3-4mm) than GBR alone, especially in the aesthetic zone where tissue support is critical.<sup>8</sup> After adequate healing, the grafted site provided sufficient ridge dimension for implant placement with optimal stability and favourable aesthetic integration. Provisionalisation played a key role in sculpting peri-implant soft tissue, achieving natural emergence profile and gingival symmetry.<sup>9</sup>

While autogenous graft may produce potential donor site morbidity such as paraesthesia or post-operative discomfort, none were encountered in this case, emphasising the safety of proper surgical technique and anatomical planning.<sup>7</sup>

This case demonstrates the successful use of mandibular symphyseal autografts in reconstructing anterior maxillary ridge deficiencies associated with congenital tooth agenesis, supporting implant placement and long-term aesthetic function.

**Conflict of interest:** None.

## REFERENCES

1. Brook AH. A unifying aetiological explanation for anomalies of human tooth number and size. *Arch Oral Biol.* 1984;29(5):373-8.
2. Addy L, Bishop K, Knox J. Modern restorative management of patients with congenitally missing teeth: 2. Orthodontic and restorative considerations. *Dent Update.* 2006 Dec 2;33(10):592-5.
3. Burchardt H. Biology of bone transplantation. *Orthop Clin North Am.* 1987 Apr;18(2):187-96.
4. Polder BJ, Van't Hof MA, Van Der Linden FPGM, Kuijpers-Jagtman AM. A meta-analysis of the prevalence of dental agenesis of permanent teeth. *Community Dent Oral Epidemiol.* 2004 June;32(3):217-26.
5. Chiapasco M, Casentini P, Zaniboni M. Bone augmentation procedures in implant dentistry. *Int J Oral Maxillofac Implants.* 2009;24 Suppl:237-59.
6. Nyström E, Legrell PE, Forssell Å, Kahnberg KE. Combined use of bone grafts and implants in the severely resorbed maxilla. *Int J Oral Maxillofac Surg.* 1995 Feb;24(1):20-5.
7. Misch CM. Comparison of intraoral donor sites for onlay grafting prior to implant placement. *Int J Oral Maxillofac Implants.* 1997;12(6):767-76.
8. Toscano N. The art of block grafting: A review of the surgical protocol for reconstruction of alveolar ridge deficiency. *J Implant Adv Clin Dent.* 2010;2(2):45-66.
9. Esquivel J, Gomez Meda R, Villarroel M. Timing implant provisionalisation: Decision-making and systematic workflow. *J Esthet Restor Dent.* 2024 June;36(6):858-67.