

Z-plasty Frenectomy: An Aesthetic Approach for an Aberrant Labial Frenum

Dr. Sushmita Baral,¹ Dr. Sajeev Shrestha,¹ Dr. Suresh Bhandari¹

¹Department of Periodontology and Oral Implantology, College of Dental Surgery, B.P. Koirala Institute of Health Sciences, Dharan, Sunsari, Nepal.

ABSTRACT

Aberrant frenum can cause midline diastema, gingival recession, speech impairment, and inadequate vestibular depth. It can be treated by either frenotomy or frenectomy. Frenectomy can be accomplished by routine scalpel technique, electrocautery, or by using laser. Several surgical techniques including simple classic technique, Millers technique, V-Y plasty, and Z-plasty are used to treat an aberrant frenum. This case report describes treatment of an aberrant frenum using Z-plasty technique in a 20-year-old patient.

Keywords: Aberrant frenum; frenectomy; z-plasty.

INTRODUCTION

A frenum is a fold of mucous membrane which contains muscle and connective tissue fibres that attach the lip and the cheek to the alveolar mucosa, the gingiva, and the underlying periosteum.¹ Several surgical techniques including simple classic technique, Miller's technique, V-Y plasty, and Z-plasty are used to treat aberrant frenum. Placek et al. (1974) have classified frenum depending upon the extension of attachment of fibres as mucosal, gingival, papillary and papillary penetrating.² Aberrant frenum is an abnormal frenum in shape, size, attachment or location.³ Among several techniques, Z-plasty is a plastic technique used to improve the functional and cosmetic appearance of scars.⁴ It is indicated for hypertrophic frenum with low insertion, midline diastema and a shallow vestibule.⁵ It has several advantages such as minimal scar formation, excellent colour matching, shortens patient recovery, and enhances patient's aesthetic outcomes.

CASE REPORT

A 20-year-old female reported to the Department of Periodontology and Oral Implantology, College of Dental Surgery, B.P. Koirala Institute of Health Sciences with a chief complaint of difficulty in brushing teeth in the upper front region of jaw for three years with no relevant medical history. On intraoral examination, a thick, broad, enlarged papillary maxillary frenum with inadequate vestibular depth was observed (Figure 1).⁵ Tension test was positive. Oral hygiene status of patient was poor. Maxillary labial frenectomy using Z-plasty technique was planned. Patient was explained about the treatment procedure for high frenal attachment and written informed consent was obtained. Non-surgical periodontal therapy was performed two weeks before the surgical procedure. The blood investigation was within the normal limit.

Preprocedural mouth rinse using 0.2% chlorhexidine solution was performed. Extraoral antiseptics was done by 5% povidone-iodine solution. Local anaesthetic infiltration using 2% lignocaine with adrenaline 1:200,000 was administered in the depth of vestibule with respect to 11, 21 (according to two-digit teeth numbering system). A vertical incision extending from coronal to apical end was given over the maxillary labial frenum using a 15 number

Correspondence

Dr. Sushmita Baral
Email: sushmitabaral12@hotmail.com



Citation

Baral S, Shrestha S, Bhandari S. Z-plasty Frenectomy: An Aesthetic Approach for an Aberrant Labial Frenum. J Nepal Soc Perio Oral Implantol. 2024 Jul-Dec;8(16):94-7.

surgical blade (Figure 2, 3). At the coronal and apical ends of the vertical incision, two lateral incisions of same length were given at about 60°(Figure 4). Adequate undermining of the surrounding tissues was performed in order to properly mobilise the flaps (Figure 5). The two triangular flaps were rotated and then transposed to the opposite side of the apex of each flap (Figure 6). Flaps were stabilised in the new position by (4-0 silk) interrupted sutures (Figure 7). Periodontal dressing (Coe-Pak) was then placed over the surgical area. Post-surgical instructions were

given. Patient was advised to refrain from brushing at the surgical site for two weeks. Patient was prescribed 0.2% chlorhexidine gluconate mouthrinse twice daily for 10 days and analgesics were prescribed (combination of ibuprofen 400 mg and paracetamol 325 mg) for two days then, if required. The sutures were removed in two weeks (Figure 8). On recall after one month, healing was uneventful with minimal scar formation (Figure 9). After six months, no hypertrophic scar was observed with excellent tissue match (Figure 10).

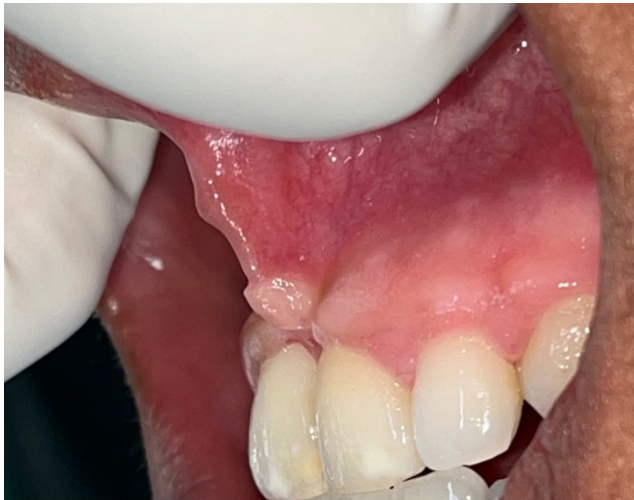

Figure 1: Lateral view of papillary maxillary frenum.

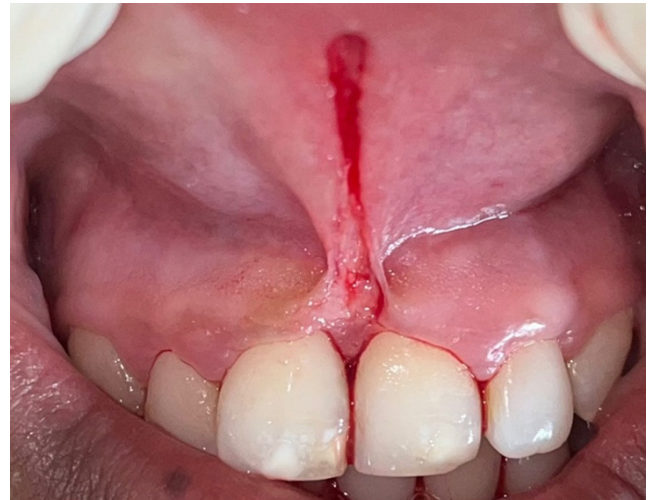

Figure 2: Vertical incision given along the length of the frenum.



Figure 3: Excised frenum tissue.

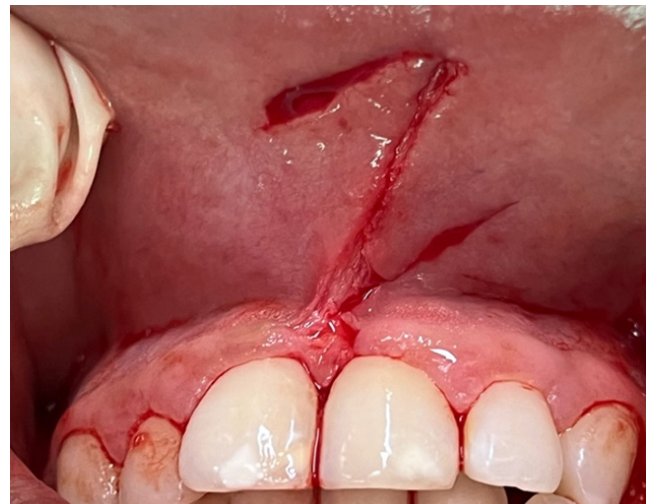

Figure 4: Two horizontal incision at 60° to the vertical incision.

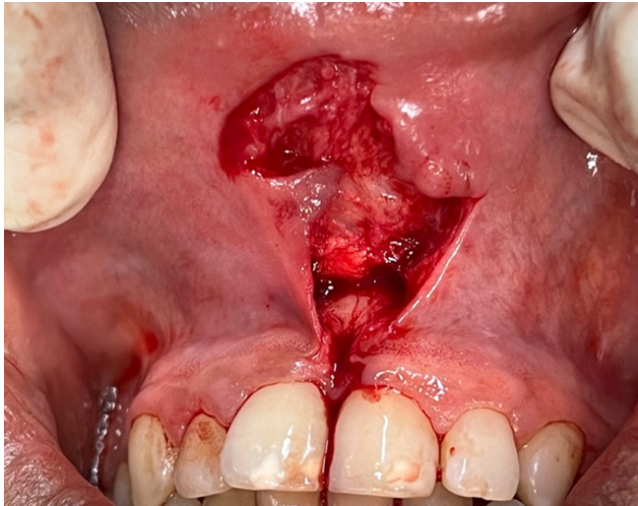


Figure 5: Undermining of the tissue.

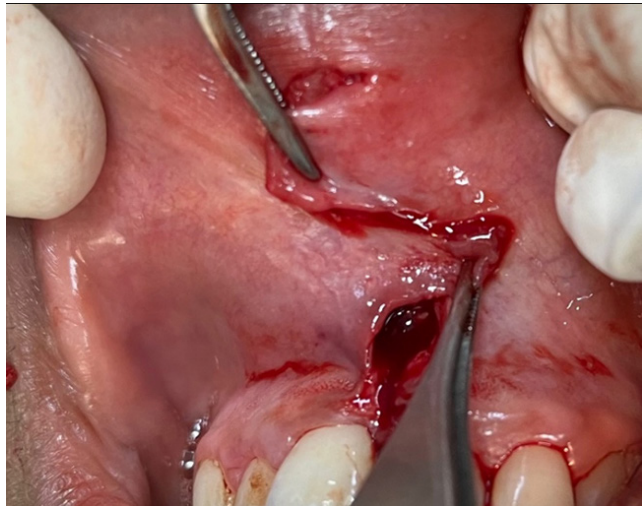


Figure 6: Two triangular flaps rotated and transposed to the opposite side.

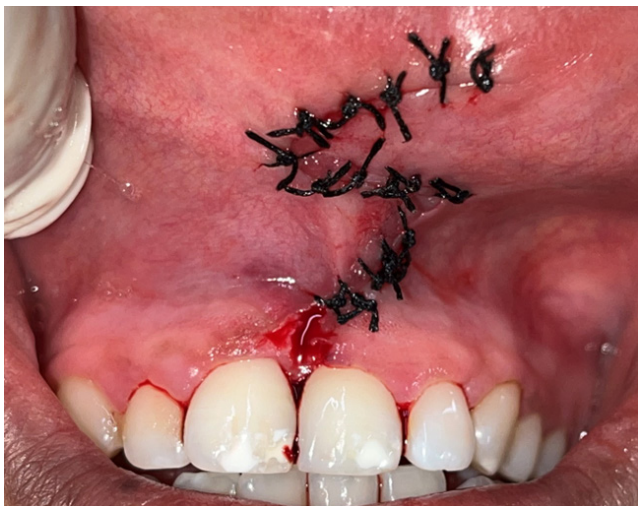

Figure 7: Flaps stabilised by interrupted suture.

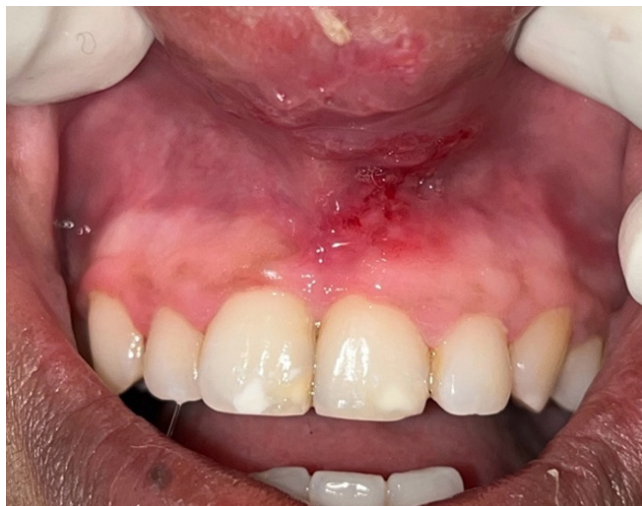

Figure 8: After suture removal in two weeks.

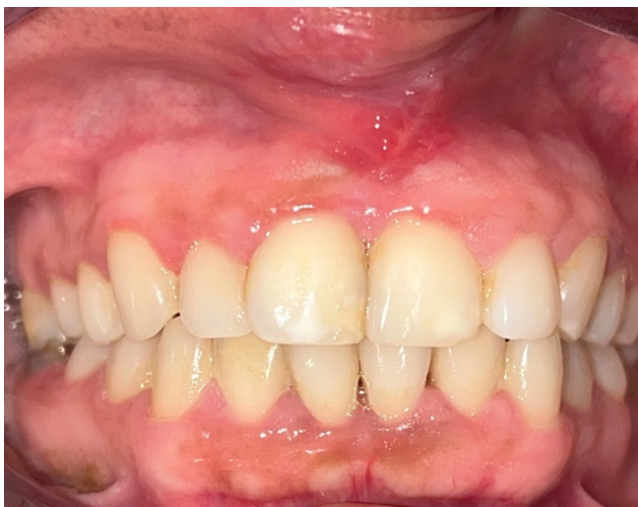

Figure 9: One month follow up.

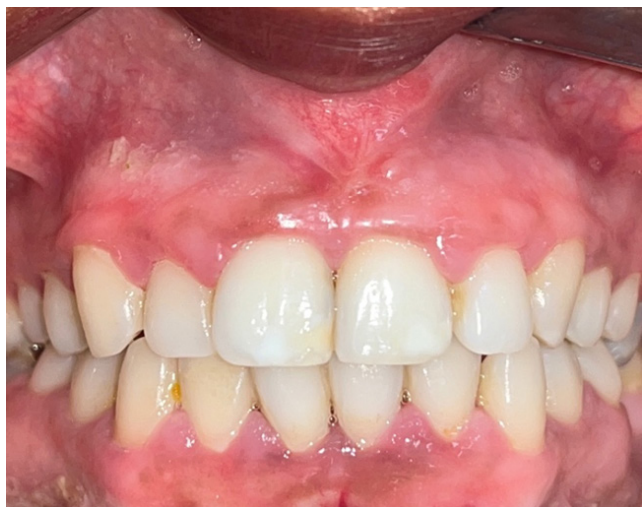

Figure 10: Six month follow up.

DISCUSSION

The prevalence of different types of labial frenum attachment and its significance in periodontal health is an important aspect of treatment plan. In Nepali population, the prevalence of frenum attachment is: gingival (65.30%), mucosal (18.70%), papillary (11.10%), and papillary penetrating (5%) in maxilla.⁶ Aberrant frenum are detected visually, by applying tension over the frenum to see the movement of the papillary tip or blanching produced due to ischaemia of the region.⁷ Various frenectomy procedures have been introduced so far. These include the classic technique, Miller's technique, V-Y plasty, Z-plasty, electrocautery, and laser. The choice of frenectomy procedure will depend on the patient's individual need, the type of frenum attachment and the clinician's preferences. Primary healing takes place by using scalpel technique, so this technique was used. The classic technique leaves a longitudinal surgical incision and scarring, which may lead to periodontal problems and an unaesthetic appearance there by necessitating other modifications. Factors such as inadequate surgical excision, poor wound healing and lack of post-operative care can lead to recurrence. The purpose of using Z-plasty in this case was removal of hypertrophic frenum and deepening of vestibule with minimum scarring. Z-plasty was initially introduced in 1856 by Denonvilliers to treat eyelid scars but has now been used in every part of the body.⁷ Z-plasty is a plastic surgery technique that improves the function and cosmetic appearance of scars.

This procedure enables the clinician to remove the fibrous band of frenum as well as helps in vertical deepening of the vestibule. The Z pattern is effective as it promotes the redistribution of tension on the skin and mucous membrane. It helps in minimising the scar formation and has a camouflaging effect. Two components determine the performance and tissue-lengthening of Z-plasty - the size of the angle and the length of the centre line of 'Z'.⁸ An angle of 60° in Z-plasty gives a gain of 75% in tissue length.¹⁰ Angle more than 60° is avoided as it increases the tension during the transposition and closure of flaps. Flap necrosis, haemorrhage, wound infection, and sloughing of the flap due to excessive wound tension are all possible consequences of Z-plasty frenectomy.¹⁰ However, using a precise and careful tissue manipulation has prevented such complications in this case.

SUMMARY

In this clinical report, Z-plasty frenectomy was performed to treat the patient's aberrant frenum. Though technique sensitive, it is reliable and has less tissue contractures after healing. The use of this technique in this case has shown minimal scar formation resulting in better functional and cosmetic appearance.

ACKNOWLEDGEMENTS

None.

Conflict of interest: None.

REFERENCES

1. Devishree, Gujjari SK, Shubhanshini PV. Frenectomy: A review with the reports of surgical techniques. *J Clin Diagn Res.* 2012 Nov;6(9):1587-92.
2. Mirko P, Miroslav S, Lubor M. Significance of the labial frenum attachment in periodontal disease in man. Part 1. Classification and epidemiology of the labial frenum attachment. *J Periodontol.* 1974 Dec;45(12):891-4.
3. Kundu N, Nair V, Chattopadhyay S. Frenectomy using scalpel in the VY- Plasty technique - A case report. *Journal of Case Reports in Medical Science.* 2017;7:8-12.
4. Menhadji P, Raindi DS, Malhi M, et al. Z-frenuloplasty: A versatile and effective technique. *Dental Update.* 2022 Mar;49(3):227-31.
5. Mehrotra K, Majhi SS, Riveni MG, et al. Z-plasty: An aesthetic approach for maxillary labial frenum. *Archives of Dentistry and Oral Health.* 2018;1(2):13-7.
6. Rijal AH, Humagain M, Lamichhane S. Prevalence of maxillary and mandibular frenal attachment and its association with age, gender, and oral hygiene status in Nepali population seeking dental treatment. *International Journal of Dentistry* 2024; 2024:1-10.
7. Sinha J, Kumar V, Tripathi AK, et al. Untangle lip through Z-plasty. *BMJ Case Rep.* 2014 Sep 19;2014:bcr2014206528.
8. Damasceno EL, Silva MS, Dias KSPA. Z plasty - An aesthetic approach to frenectomy: case report. *International Journal of Development Research.* 2020;10:38053-056.
9. Garg S, Dahiya N, Gupta S. Surgical scar revision: An overview. *J Cutan Aesthet Surg.* 2014 Jan;7(1):3-13.
10. Endang S, Adam Mardiana AA, Irawaty Djais AI, et al. Z plasty - An aesthetic surgery for aberrant labial frenum: A Case Report. *The International Online Seminar Series on Periodontology in conjunction with Scientific Seminar.* 2022;144-50.