

## A Case Report of a Free Gingival Graft Done to Rectify Gingival Recession

Dr. Rahul Shah,<sup>1</sup> Dr. Chirag Shah,<sup>2</sup> Dr. Kunjal Chirag Shah,<sup>2</sup>  
Dr. Bhavika Shah,<sup>3</sup> Dr. Praveena Lakshmi<sup>1</sup>

<sup>1</sup>Department of Periodontology and Implantology, College of Dental Sciences, Ahmedabad, Gujarat, India;

<sup>2</sup>Parshwa Multi Specialty Dental Clinic and Implant Centre, Paldi, Ahmedabad, Gujarat, India;

<sup>3</sup>Elite Dental Care Centre, Paldi, Ahmedabad, Gujarat, India.

### ABSTRACT

Gingival recession is associated with functional problems such as dentinal hypersensitivity and root caries. This case report describes treatment of gingival recession with free gingival graft technique. Free gingival grafting was done in relation to 31. Split-thickness flap was elevated in the region of 31. The area to be taken for grafting was selected between first and second premolar. The graft was placed on the recipient bed and suturing was done. Complete recession coverage was observed. Results of free gingival grafting show fairly acceptable results in terms of tissue gain suggesting free gingival graft as a viable option.

**Keywords:** Gingival recession; periodontal attachment loss; pre-existing condition coverage.

### INTRODUCTION

Gingival recession is the displacement of the soft tissue margin apical to the cementoenamel junction (CEJ) with exposure of the root surface. The distance between the CEJ and gingival margin gives an estimation of the level of recession. There are many aetiologic factors for recession such as periodontal disease, accumulations, inflammation, aggressive tooth brushing and dominant roots. It is also associated with functional problems such as dentinal hypersensitivity and root caries.<sup>1</sup> The palatal masticatory mucosa is widely used as a donor site in gingival recession treatment. In this case, free gingival grafting was chosen as the procedure to be followed.

### CASE REPORT

A 23-year-old female patient came to the clinic with chief complaint of receding gums in lower front tooth. Upon inspection, gingival recession was observed in the region of 31 (according to two-digit numbering system). The patient was scheduled to undergo mucogingival surgery. Before any incisions, the exposed root surface was carefully scaled and root planed. A 3-4 mm wide recipient connective tissue bed was prepared apical and lateral to the recession defect.

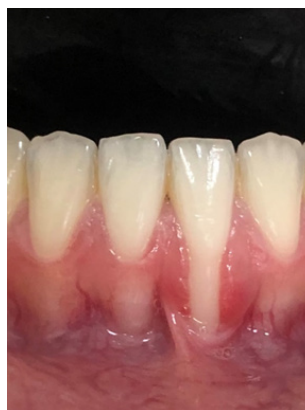

Figure 1: Preoperative view.

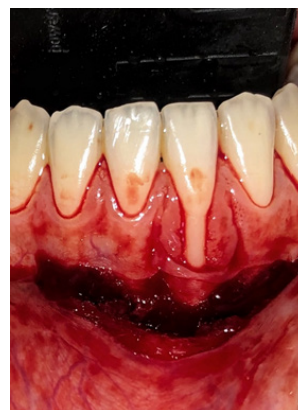

Figure 2: Vestibular extension done.

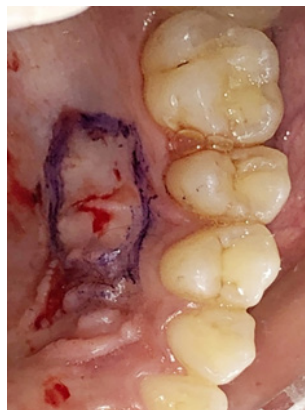

Figure 3: Area demarcated to be harvested for grafting.

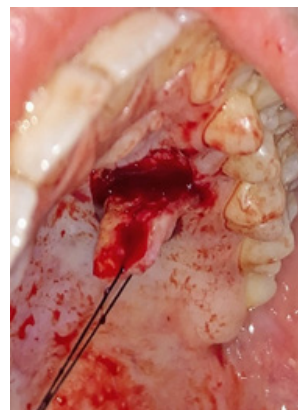


Figure 4: Palatal graft obtained.

The area was demarcated by first placing a horizontal incision, at the level of the CEJ, in the interdental tissue on each side of the tooth to be treated. Subsequently, two vertical incisions, extending from the incision line placed in the

### Correspondence

Dr. Praveena Lakshmi

Email: praveena\_lakshmi@hotmail.com



### Citation

Shah R, Shah C, Shah KC, Shah B, Lakshmi P. A Case Report of a Free Gingival Graft Done to Rectify Gingival Recession. J Nepal Soc Perio Oral Implantol. 2021 Jul-Dec;5(10):100-2

This is an open access journal, and articles are distributed under the terms of the Creative Commons Attribution CC BY 4.0 Licence.

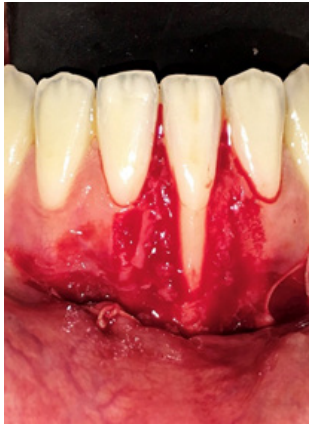


Figure 5: Recipient bed prepared.

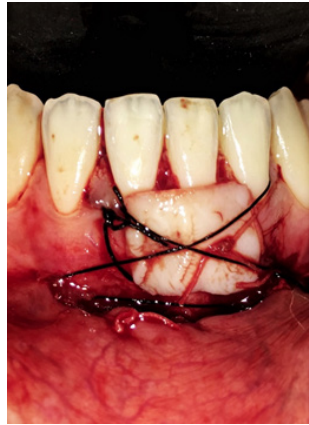

Figure 6: Sutures in place.

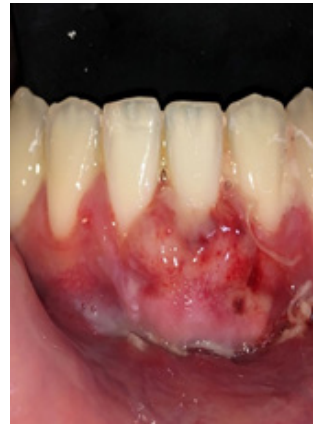

Figure 7: Post-operative healing.

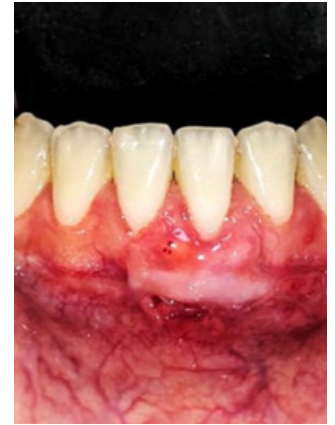

Figure 8: Healing after 15 days.

interdental tissue to a level approximately 4-5 mm apical to the recession, were placed. A horizontal incision was then made connecting the two vertical incisions at their apical termination. Starting from an intracrevicular incision, a split incision was made to sharply dissect the epithelium and the outer portion of the connective tissue within the demarcated area.

A tin foil template of the recipient site was prepared. This template was transferred to the donor site, the palatal mucosa in the region of the premolars, and the required size of the graft was outlined by a shallow incision. An epithelialised free gingival graft with a thickness of 2-3 mm was then dissected from the donor area. The graft was immediately placed on the prepared recipient bed. Holding sutures were given in the periosteum and in the adjacent attached gingiva. Adequate numbers of sutures were placed to secure close adaptation of the graft to the underlying connective tissue bed and root surface. Following the control of bleeding, a periodontal dressing was applied to the wound in the donor area in the palate. An acrylic plate was given to maintain the dressing in place during the healing phase.<sup>4</sup>

## DISCUSSION

Gingival recession is an issue which is faced both by the clinician and the patient. The distance between the CEJ and gingival margin gives an estimation of the level of recession.<sup>2</sup> Miller<sup>3</sup> proposed a useful recession defect classification based on the height of the interproximal papillae and interdental bone adjacent to the defect area, and the relation of the gingival margin to the mucogingival junction:

**Class I:** Marginal tissue recession not extending to the mucogingival junction (MGJ). No loss of interdental bone or soft tissue;

**Class II:** Marginal recession extending to or beyond the MGJ. No loss of interdental bone or soft tissue;

**Class III:** Marginal tissue recession extends to or beyond the MGJ. Loss of interdental bone or soft tissue is apical to the CEJ but coronal to the apical extent of the marginal tissue recession; and

**Class IV:** Marginal tissue recession extends to or beyond the MGJ. Loss of interdental bone extends to level apical to the extent of the marginal tissue recession.

In the current era, various treatment modalities are available. The ideal procedure to be chosen depends upon local anatomic conditions, choice of operator and patient's comfort. The presence of adequate keratinised gingiva serves as a barrier to physical trauma and future progression of recession. There is no universal harmony on amount of attached gingiva for periodontal health, but it is common opinion that area with less than 2 mm of keratinised gingiva is more viable for recession.<sup>4</sup>

The key factors which determine the successful management of gingival recessions are the identification of its etiologic agents and their elimination, the assessment of the degree of tissue involvement and last but not least, the selection and the careful implementation of the appropriate surgical procedure in order to achieve optimal root coverage, improved soft tissue aesthetics and reduced sensitivity. The surgical root coverage techniques which are available right now, are: (i) Free epithelialised gingival graft, (ii) Subepithelial connective tissue graft, (iii) Semilunar flap, (iv) Coronally advanced flap, (v) Guided tissue regeneration.<sup>1</sup>

A previous systematic review showed that the connective tissue graft (CTG) plus coronally advanced flap (CAF) is considered the gold standard technique in treatment of gingival recessions. A possible explanation for the clinical efficacy of CTG may be related to the specific healing model of the procedure. In fact, the high stability of the wound over CTG is associated with graft vascularisation which is originated from both the periodontal plexus and the overlying flap leading to a complete blood supply for the graft after two weeks.<sup>5</sup>

However, CTG has a number of disadvantages: a secondary harvesting surgery for donor tissue is required; increased morbidity may be associated with the donor surgery; and a limited amount of donor tissue is available, limiting the number of defect sites treated per patient visit.<sup>6</sup>

There are various surgical techniques available for root coverage like rotational flaps, coronally advanced flap, free gingival graft, guided tissue regeneration, connective tissue graft and combination of these.<sup>7</sup> Despite various advances in technique of correction of gingival recession, free gingival graft continues to be a reliable procedure for increasing the width of keratinised gingiva and stopping the progression of gingival recession. At present, even though the free gingival grafts are tailing behind subepithelial connective tissue grafts as far as root coverage is concerned, they still hold superior edge in considerations like: procedure being simple, multiple teeth can be treated at one time, easy tissue handling, and can be performed when keratinised gingiva adjacent to involved is insufficient.<sup>8</sup>

Free gingival graft is a versatile mode of treatment which can be used to cover denuded roots and to increase the width of attached gingiva. It can be used as a single step or two step procedure. The technique proposed by Miller is a one-step procedure or the direct approach, whereas the one described by Bernimoulin<sup>9</sup> et al. involves two surgical steps and is referred to as the indirect approach.

It is demonstrated that free gingival graft has slightly less chances of success and predictability as compared to connective tissue grafts. There are different reasons for incomplete root coverage like improper classification of marginal tissue recession, inadequate root planing, improper preparation of recipient site, inadequate size of interdental papilla, inadequate graft size and thickness, dehydration of donor tissue, inadequate adaptation of graft to root and remaining periosteal bed, failure to stabilise the graft, excess or prolonged pressure in coaptation of sutured graft, reduction of inflammation prior to graft, trauma to graft during initial healing, excessive smoking. Free gingival graft, though lagging behind the connective tissue graft in terms of accuracy, still holds an edge as far as simplicity and invasiveness of the procedure is concerned. Free gingival graft was used in this study because: (i) Shallow palatal vault was observed in the studied population which was not suitable for harvesting the connective tissue graft. (ii) The patient presented with relatively thin gingiva phenotype. Technique such as laterally placed flap could not be implemented as chances of donor tissue recession was there. Therefore, free gingival grafting is still a viable option and can be a preferred mode of surgery for treatment of gingival recession in cases where connective tissue grafting is not ideal.

**Conflict of Interest:** None.

## REFERENCES

1. Joshipura KJ, Kent RL, De Paola PF. Gingival recession: Intra-oral distribution and associated factors. *J Periodontol.* 1994; 65:864-71.
2. Jan Lindhe, Niklaus Peter Lang. *Clinical Periodontology and Implant Dentistry.* 6th ed. Chichester, West Sussex, UK : Wiley Blackwell. 2015;972.
3. Miller PD Jr. A classification of marginal tissue recession. *J Periodontics Restor Dent.* 1985;5(2):8-13.
4. Lang NP, Loe H. The relationship between the width of keratinized gingiva and gingival health. *J Periodontol.* 1972;43:623-7.
5. Guiha R. Histological evaluation of healing and revascularization of the subepithelial connective tissue graft. *J Periodontol.* 2001;72(4):470-8.
6. Griffin TJ, Cheung WS, Zavras AI, Damoulis PD. Postoperative complications following gingival augmentation procedures. *J Periodontol.* 2006. Dec;77(12):2070-9.
7. Windisch P, Molnar B. Surgical management of gingival recession using autogenous soft tissue grafts. *Clin Dent Rev.* 2019;3(18):1-12.
8. Hangorsky U, Bissada NF. Clinical assessment of free gingival graft effectiveness on the maintenance of periodontal health. *J Periodontol* 1980;51:274-8.
9. Bernimoulin JP, Luscher B, Muhlemann HR. Coronally repositioned periodontal flap Clinical evaluation after one year. *J Clin Periodontol.* 1975;2:1-13.