

Maxillary Sinus Septa: Prevalence and Variation with Gender and Location

Dr. Kamana Neupane,¹ Dr. Bhageshwar Dhama,¹ Dr. Nashib Pandey,¹
Dr. Deepa Aryal,¹ Dr. Sushmit Koju,² Dr. Nisha Maharjan²

¹Department of Periodontics, Kantipur Dental College Teaching Hospital and Research Centre, Basundhara, Kathmandu, Nepal;

²Department of Oral Pathology, Kantipur Dental College Teaching Hospital and Research Centre, Basundhara, Kathmandu, Nepal.

ABSTRACT

Introduction: Maxillary sinus septa are partitions of cortical bone dividing the sinus into multiple compartments. Their presence and dimension are of relevance to periodontists, oral and maxillofacial surgeons as well as otolaryngologists.

Objective: To determine the prevalence of maxillary sinus septa and its variation with gender and location in sampled Nepali population.

Methods: An analytical cross-sectional study was conducted in Department of Periodontics, Kantipur Dental College Teaching Hospital and Research Centre after ethical clearance from Institutional Review Committee. Convenience sampling was done for 433 orthopantomograms (OPGs) with clearly visible maxillary sinus and absence of pathological or developmental changes. Each OPG was observed for presence of septa. Presence or absence of septa was noted along with position and site of septa. Gender of subjects was also noted. Statistical analysis was performed via SPSS 21.0.

Results: Among observed radiographs, 148 (34.18%) showed presence of maxillary sinus septa. Septa were more prevalent among males (84, 56.76%) than females 64 (43.24%); with statistically significant difference ($P < 0.05$). Unilateral occurrence (97, 65.54%) of septa was greater than bilateral (51, 34.46%).

Conclusion: This study may serve as baseline data for prevalence of maxillary sinus septa and may aid in treatment planning during dental implant placements and surgical procedures of maxillary sinus.

Keywords: Maxillary sinus; prevalence; septa; variation.

INTRODUCTION

Maxillary sinus septa are the barriers of cortical bone that divide the maxillary sinus floor into multiple compartments, known as recesses.¹ The role of the septum is to separate the sinus into two or more antra and to strengthen the bony structure of the sinus.² The presence and dimension of maxillary septa are of practical relevance to periodontists, oral and maxillofacial surgeons as well as otolaryngologists.³

In relevance to the placement of implants, septa seen in the floor of the sinus or along the lateral wall can interfere with its placement either directly by being present in its area of placement or indirectly by hindering the elevation of the wall during lateral sinus approach.⁴ The prevalence of mul-

tle septa in the maxillary sinus varies from 7% to 58% in the literature.⁵ However, possible differences between ethnic groups may contribute to these differences.⁵ Therefore, this study will provide an insight on the prevalence of maxillary sinus septa in sampled Nepali population.

METHODS

An analytical cross-sectional observational study was carried out in the Department of Periodontics, Kantipur Dental College Teaching Hospital and Research Centre after ethical approval from the institution. The study was carried out for a period of three months. The sample size of 433 was obtained using the formula:

$$n = \frac{Z^2pq}{e^2}$$

Where,

n = required sample size

Z = z deviate corresponding to desired reliability level (at 95%, 1.96)

Correspondence

Dr. Kamana Neupane

Email: drkneupane@gmail.com

Citation

Neupane K, Dhama M, Pandey N, Aryal D, Koju S, Maharjan N. Maxillary Sinus Septa: Prevalence and Variation with Gender and Location. J Nepal Soc Perio Oral Implantol. 2021 Jul-Dec;5(10):82-6



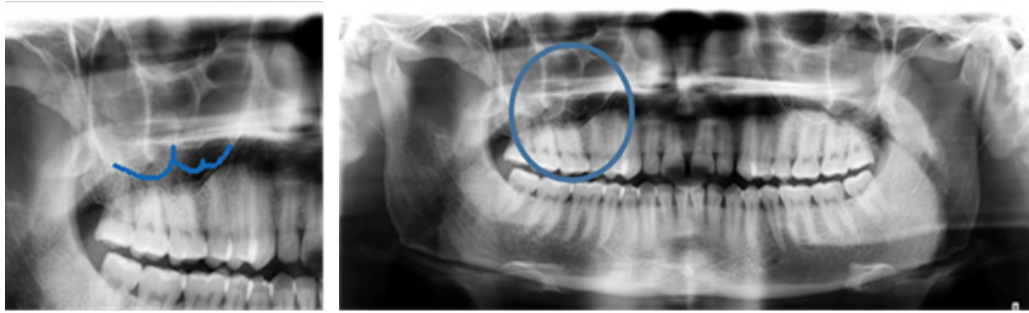

Figure 1: Panoramic radiograph showing septa in maxillary sinus.

e = precision level = 0.04

p = proportion in the target population = 0.236⁶

q = 1-p (proportion in the target population) = 0.764

The study constituted of good quality standard panoramic radiographs with clearly visible maxillary sinus of patients who had full complement of teeth taken as part of pretreatment planning or oral diagnosis. Each patient was exposed to panoramic X-ray by Carestream (CS9300, Kodak) at 74kv, 12 mA for 14.3 seconds exposure time with head positioning according to the manufacturer’s specified position. Radiographs of patients with evidence of previous intrusion procedure of sinus, any pathological or developmental changes in maxillary sinus, poor quality radiographs lacking adequate contrast, distorted images and unclear radiographs were excluded.

Orthopantomograms (OPGs) which fulfilled the inclusion criteria of the study were taken and were observed by single examiner for the presence of septa in the maxillary sinus. Presence or absence of septa were noted along with their position and site (Figure 1). Demographic details like age

and gender were noted. Data were compiled and analysed using Statistical package for the Social Sciences (SPSS) software version 21 (IBM Corp., Armonk, N.Y., USA). Descriptive analysis was performed. Chi- Square test was applied to check the association between gender and presence of septa and site. P value < 0.05 was taken as statistically significant.

RESULTS

The study consisted of OPGs of 217 (50.12%) males and 216 (49.88%) females. Maxillary sinus septa was present in 148 (34.18%) study participants. The study group with septa showed that 84 (56.76%) were males and 64 (43.24%) were females and the finding was statistically significant (P value = 0.046, Table 1).

Based on the occurrence, 97 (65.54%) septa had unilateral occurrence whereas 51 (34.16%) occurred bilaterally. Among unilateral presentation, right side showed more prevalence (56; 57.73%) compared with the left side (41; 42.27%). Both unilateral as well as bilateral presentation showed greater prevalence among males i.e. 49 (50.52%), 35 (68.63%) respectively, and the difference was statistically significant with P value= 0.035 (Table 2).

Table 1: Prevalence of maxillary sinus septa as per gender, n (%).

Gender	Presence of Septa		P value
	Absent	Present	
Male	133 (46.67)	84 (56.76)	0.046*
Female	152 (53.33)	64 (43.24)	
Total	285 (100)	148 (100)	

*P value <0.05; Statistically Significant

Table 2: Unilateral/ bilateral prevalence of maxillary sinus septa as per gender, n (%).

Gender	Site of Maxillary Sinus Septa		P value
	Unilateral	Bilateral	
Male	49 (50.52)	35 (68.63)	0.046*
Female	48 (49.48)	16 (31.37)	
Total	97 (100)	51 (100)	

*P value <0.05; Statistically Significant

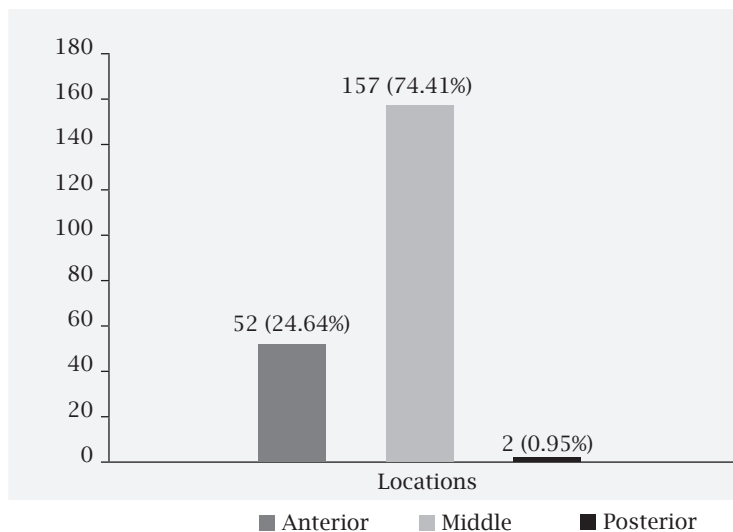


Figure 2: Bar diagram showing frequency distribution of prevalence of maxillary sinus septa based on the location.

The prevalence of uniseptate septa were greater than multiseptate septa being 184 (92.93%) and 14 (7.07%) respectively. The total number of septa in the present study was found to be 211. The highest number of septa were located in the middle region extending from distal aspect of second premolar to mesial aspect of second molar (157, 74.41%) followed by anterior region which is mesial from middle region (52, 24.64%) and posterior region which is distal to second molar (2, 0.95%, Figure 2).

DISCUSSION

Maxillary sinus was first analysed by Underwood AS for its characteristics and presence of septa, thus it is also referred as Underwood's septa.⁷ Underwood reported that the septa are formed because of the different eruption phases of the teeth.⁷ Structurally, they have been described as inverted gothic arches arising from the inferior and lateral walls of the sinus and coming to a sharp edge along its most apical border; they can divide the sinus into two or more compartments.⁸ Neivert and Harry proposed that the septa are derived from the fingerlike projections produced by the embryologic out-pouching of the ethmoid infundibulum, where the contiguous walls do not absorb.⁹ Vinter et al. observed that resorption of the maxillary alveolar process proceeds irregularly in different regions leaving bony crests on the sinus floor.¹⁰

Krennmair et al. (1999) proposed a classification of congenital and acquired septa into primary septa, which can develop in all regions of the maxillary sinus, and arise during development of the maxilla, and secondary septa, which arise from irregular pneumatization of the sinus floor following

tooth loss.¹¹ However, the exact mechanism responsible for maxillary septum development is still unclear, although a role for the irregular pneumatization of the sinus floor following tooth loss has been suggested.⁵

The present study observed the maxillary sinus septa in panoramic radiographs. This method is the most commonly used diagnostic aid in pre-operative sinus evaluation, and is affordable.¹² The result showed that the septa were more prevalent in males. Furthermore, the unilateral septa were more prevalent in male. These findings were statistically significant. Similar observations were reported in other studies.^{2,5,13,14} However, female prevalence have been observed.^{2,15} The mean maximum bite force in males was observed to be significantly higher than in females, which could explain the difference in septa prevalence based on gender.¹⁶

The right maxilla showed greater prevalence of septa as compared to the left side (57.73% and 42.27% respectively). Other studies also showed the greater presence of septa in the right side than on the left.^{4,6} Park et al.² observed a greater prevalence on the left side. However, their finding was not statistically significant.

Septa are classified under headings such as septa location, morphology, and orientation. When septa are evaluated in terms of location, anterior septa exist between the first and second premolar region (sinus anterior wall) and the mesial of the first molar. Middle region septa exist between the mesial of the first molar and the mesial of the second molar. Posterior septa are between the distal of the second molar and the posterior sinus wall.¹⁷ The present study showed

that the highest number of septa was present on the middle region followed by anterior and posterior region (74.41%, 24.64% and 0.95% respectively). Similar prevalence of septa on the middle region were revealed by few other studies^{2,5,14} whilst few studies reported anterior septa being more prevalent.^{18,19} Additional studies have found prevalence in the posterior region.²⁰⁻²² Alurt et al.²⁰ observed posterior prevalence in both CBCT (cone-beam computed tomography) and panoramic radiograph.

Owing to the increase in sinus floor elevation procedures by general practitioners, more complications of sinus floor elevation are seen. This is probably due to the lack of formal training or inadequate training for performing this type of surgery and ignorance about the anatomy of the maxillary sinus. This emphasises need for studies related to the maxillary sinus. The perforation of the Schneiderian membrane has been reported to be as high as 44%.^{23,24} One of the possible causes of such a high perforation rate of the Schneiderian membrane during sinus floor elevation is the presence of septa.²⁴ Presence of septa in the floor of the sinus or along the lateral wall, can interfere with the placement of an implant either directly by being present in its area of

placement or indirectly by hindering the elevation of the wall during lateral sinus approach.⁴

CONCLUSION

Septa in the maxillary sinus was more prevalent amongst males. Unilateral presentation of septa was prevalent than bilateral. This signifies practitioner to be cautious during treatment involving the maxillary sinus; specially on the right side. However, further studies based on other imaging modalities as well as clinical correlation is needed for supporting the findings.

ACKNOWLEDGEMENT

We would like to acknowledge Department of Oral Medicine and Radiology for the technical support. We would also like to thank Dr. Arjun Hari Rijal for his help during the conduction of the study.

Conflict of Interest: This study had been presented as paper by the authors in 2nd Annual Conference of Nepal Association for Dental Research on 19th December, 2020, Kathmandu.

REFERENCES

1. Pommer B, Ulm C, Lorenzoni M, Palmer R, Watzek G, Zechner W. Prevalence, location and morphology of maxillary sinus septa: systematic review and meta-analysis. *J Clin Periodontol.* 2012;39(8):769-73.
2. Park YB, Jeon HS, Shim JS, Lee KW, Moon HS. Analysis of the anatomy of the maxillary sinus septum using 3-dimensional computed tomography. *J Oral Maxillofac Surg.* 2011;69(4):1070-8.
3. Rysz M, Bakoń L. Maxillary sinus anatomy variation and nasal cavity width: structural computed tomography imaging. *Folia morphologica.* 2009;68(4):260-4.
4. Dandekeri SS, Hegde C, Kavassery P, Sowmya MK, Shetty B. CBCT study of morphologic variations of maxillary sinus septa in relevance to sinus augmentation procedures. *Ann Maxillofac Surg.* 2020;10(1):51-6.
5. Shen EC, Fu E, Chiu TJ, Chang V, Chiang CY, Tu HP. Prevalence and location of maxillary sinus septa in the Taiwanese population and relationship to the absence of molars. *Clin Oral Implants Res.* 2012;23(6):741-5.
6. Kannaperuman J, Natarajarathinam G, Rao AV, Muthusamy N. Cross-sectional study estimating prevalence of maxillary sinus septum in South Indian population. *J Dent Implant.* 2015;5(1):16-8.
7. Underwood AS. An inquiry into the anatomy and pathology of the maxillary sinus. *J Anat Physiol.* 1910;44(Pt 4):354-69.
8. Koymen R, Gocmen-Mas N, Karacayli U, Ortakoglu K, Ozen T, Yazici AC. Anatomic evaluation of maxillary sinus septa: Surgery and radiology. *Clin Anat.* 2009;22(5):563-70.
9. Neivert H. Symposium on maxillary sinus: Surgical anatomy of the maxillary sinus. *The Laryngoscope.* 1930;40(1):1-4.
10. Vinter I, Krmpotić-Nemanić J, Hat J, Jalsovec D. Does the alveolar process of the maxilla always disappear after tooth loss?. *Laryngorhinootologie.* 1993 Dec;72(12):605-7.
11. Krennmair G, Ulm C, Lugmayr H. Maxillary sinus septa: incidence, morphology and clinical implications. *J Craniomaxillofac Surg.* 1997;25(5):261-5.
12. Lopes LJ, Gamba TO, Bertinato JVJ, Freitas DQ. Comparison of panoramic radiography and CBCT to identify maxillary posterior roots invading the maxillary sinus. *Dentomaxillofac Radiol.* 45(6):20160043.
13. Al-Zahrani MS, Al-Ahmari MM, Al-Zahrani AA, Al-Mutairi KD, Zawawi KH. Prevalence and morphological variations of maxillary sinus septa in different age groups: a CBCT analysis. *Ann Saudi Med.* 2020 May;40(3):200-6.
14. Orhan K, Kusakci Seker B, Aksoy S, Bayindir H, Berberoğlu A, Seker E. Cone beam CT evaluation of maxillary sinus septa prevalence, height, location and morphology in children and an adult population. *Med Princ Pract.* 2013;22(1):47-53.
15. Malec M, Smektala T, Tutak M, Trybek G, Sporniak-Tutak K. Maxillary sinus septa prevalence and morphology: computed tomography based analysis. *Int J Morphol.* 2015;33(1):144-8.
16. Jain V, Mathur VP, Pillai RS, Kalra S. A preliminary study to find out maximum occlusal bite force in Indian individuals. *Indian J Dent Res.* 2014 Jun;25(3):325-30.
17. Kocak N, Alpoz E, Boyacıoğlu H. Morphological assessment of maxillary sinus septa variations with cone-beam computed tomography in a Turkish population. *Eur J Dent.* 2019;13(1):42-6.

-
18. Selcuk A, Ozcan KM, Akdogan O, Bilal N, Dere H. Variations of maxillary sinus and accompanying anatomical and pathological structures. *J Craniofac Surg.* 2008;19(1):159-64.
 19. Jang SY, Chung K, Jung S, Park HJ, Oh HK, Kook MS. Comparative study of the sinus septa between dentulous and edentulous patients by cone beam computed tomography. *Implant Dent.* 2014;23(4):477-81.
 20. Toraman Alkurt M, Peker I, Degerli S, Cebeci ARİ, Sadik E. Comparison of cone-beam computed tomography and panoramic radiographs in detecting maxillary sinus septa. *J Istanbul Univ Fac Dent.* 2016;50(3):8-14.
 21. Talo Yildirim T, Güncü GN, Colak M, Nares S, Tözüm TF. Evaluation of maxillary sinus septa: a retrospective clinical study with cone beam computerized tomography (CBCT). *Eur Rev Med Pharmacol Sci.* 2017;21(23):5306-14.
 22. Dragan E, Odri GA, Melian G, Haba D, Olszewski R. Three-dimensional evaluation of maxillary sinus septa for implant placement. *Med Sci Monit.* 2017;23:1394-400.
 23. Çakur B, Sümbüllü MA, Durna D. Relationship among schneiderian membrane, underwood's septa, and the maxillary sinus inferior border. *Clin Implant Dent Relat Res.* 2013;15(1):83-7.
 24. Schwartz-Arad D, Herzberg R, Dolev E. The prevalence of surgical complications of the sinus graft procedure and their impact on implant survival. *J Periodontol.* 2004;75(4):511-6.
-