

Prevalence and Location of Maxillary Sinus Septum and its Relation to Maxillary Sinusitis

Dr. Bhageshwar Dhama,¹ Dr. Priti Shrestha,² Dr. Ankit Saha,³
Dr. Nashib Pandey,¹ Dr. Deepa Aryal¹

¹Department of Periodontics, Kantipur Dental College, Basundhara, Kathmandu, Nepal;

²Department of Periodontics, KIST Medical College and Teaching Hospital, Imadol, Lalitpur, Nepal;

³Department of Oral Medicine and Radiology, Kantipur Dental College, Basundhara, Kathmandu, Nepal.

ABSTRACT

Introduction: Maxillary sinus septum is an anatomical variation in the maxillary sinus. Sinus septum is also an important anatomical structure that complicates sinus lift procedure during dental implant placement.

Objectives: To assess the prevalence and location of maxillary sinus septa and its relation to maxillary sinusitis using cone beam computed tomography (CBCT scan).

Methods: An analytical cross-sectional study was conducted at the Department of Periodontics and Department of Oral Medicine and Radiology, Kantipur Dental College, Kathmandu, Nepal during July 2019 to June 2020 after ethical clearance. In total, 110 subjects and 220 maxillary sinuses were included in the study for evaluation by convenience sampling. The presence of septa, their location and association with maxillary sinusitis were evaluated. Data was analysed using SPSS software with Statistical level set at $P < 0.05$ for significance.

Results: The prevalence of maxillary sinus septa in this study was 54 (49.09%). Statistically significant association was found between sinus septa with maxillary sinusitis ($p=0.038$) and location of septum in the arch ($p=0.001$).

Conclusion: Presence and distribution of maxillary sinus septa is important in planning sinus surgeries and placement of implant in maxillary posterior region.

Keywords: Cone beam computed tomography; dental implants; maxillary sinus; sinus septa.

INTRODUCTION

Dental implant therapy has become a proven and predictable treatment modality providing both conservative and aesthetic alternative compared to conventional fixed and removable prostheses.¹ However, the possibility of implant therapy depends on the availability of bone at the surgical site. Implant placement in the posterior maxilla is especially complicated due to pneumatization of the maxillary sinus leading to the reduced bone height of alveolar process.² The level of vertical bone height for implant placement may

become deficient as it has individual variation.^{3,4} Studies have demonstrated that the presence of sinus septa is a predominant risk factor for perforation of the membrane in maxillary sinus lift procedure.⁵⁻⁷ Prevalence of sinus septa has shown widely divergent values in the literature, ranging between 7% and 70%.⁸⁻¹¹ Cone beam computed tomography (CBCT) guarantees images obtained in different planes, without superimpositions, with high quality, and excellent resolution, with relatively low dose of radiation making it the best choice for evaluating the maxillary sinuses.^{12,13} However, there is limited data about prevalence of maxillary sinus septa and their relation to maxillary sinusitis. Therefore, the purpose of the present study was to examine the prevalence and location of maxillary sinus septa and their relation to maxillary sinusitis using CBCT.

METHODS

An analytical cross-sectional study was conducted at the Department of Periodontics and Department of

Correspondence

Dr. Bhageshwar Dhama

Email : dhamibhagesh@gmail.com



Citation

Dhama B, Shrestha P, Saha A, Pandey N, Aryal D. Prevalence and Location of Maxillary Sinus Septum and its Relation to Maxillary Sinusitis. J Nepal Soc Perio Oral Implantol. 2021 Jul-Dec;5(10):77-81.

Oral Medicine and Radiology, Kantipur Dental College, Basundhara, Kathmandu, Nepal. The study was conducted during July 2019 to June 2020 after getting approval from the Institutional Review Committee (Ref. 8/19). Sample size was calculated using the following formula: Sample Size (n) = z^2pq/e^2 . Where, $z=1.96$, $p=0.071$ (7.1%),⁸ $q=1-p=0.929$, $e=0.05$ (5%). Here, $n = 101.3 \approx 110$. Thus, 110 subjects and 220 maxillary sinuses were evaluated for the study. Patient visiting the Department of Periodontics and Department of Oral Medicine and Radiology with age more than 15 years were included in the study by convenience sampling after they had signed an informed consent. The subjects excluded were; patients with craniofacial lesions or anomalies, with history of trauma and/or maxillofacial surgeries, patients who presented dental implants or bone grafts in the posterior region of the maxilla either or not associated with maxillary sinus augmentation surgeries.

Cone beam computed tomography data were obtained from the CBCT images taken via CS9300 Care Stream, USA machine using the standardised protocol at 85 kV, 6.3 mA, Voxel size of 300x300x300 μm and the field of view was fixed at 17x13.5 cm. The data was then exported as

Dicom Files and the CS Imaging site was used to visualise the radiographs in axial, coronal and sagittal views and measured using inbuilt measuring tools .

The evaluations of maxillary sinus septum, prevalence, location, and maxillary sinusitis were done in axial, sagittal, cross-sectional, and reconstructed panoramic images with three-dimensional reconstructions (Figure 1). Each maxillary sinus bearing a septum was divided into three portions: anterior = mesial to distal aspect of second premolar; middle = distal aspect of second premolar to distal aspect of second molar; and posterior = distal aspect of second molar. Two examiners were trained individually with calibration exercises to identify and locate the sinus septum in the digital images of the CBCT scan. Each CBCT scan was analysed by these two examiners to confirm the presence or absence of sinus septum and location of sinus septum.

Statistical analysis was done using SPSS version 20 (IBM Corp., Armonk, N.Y., USA). Association between age, gender and presence of sinus septa was calculated using Chi-square test. Statistical level was set at $P < 0.05$ for significance.

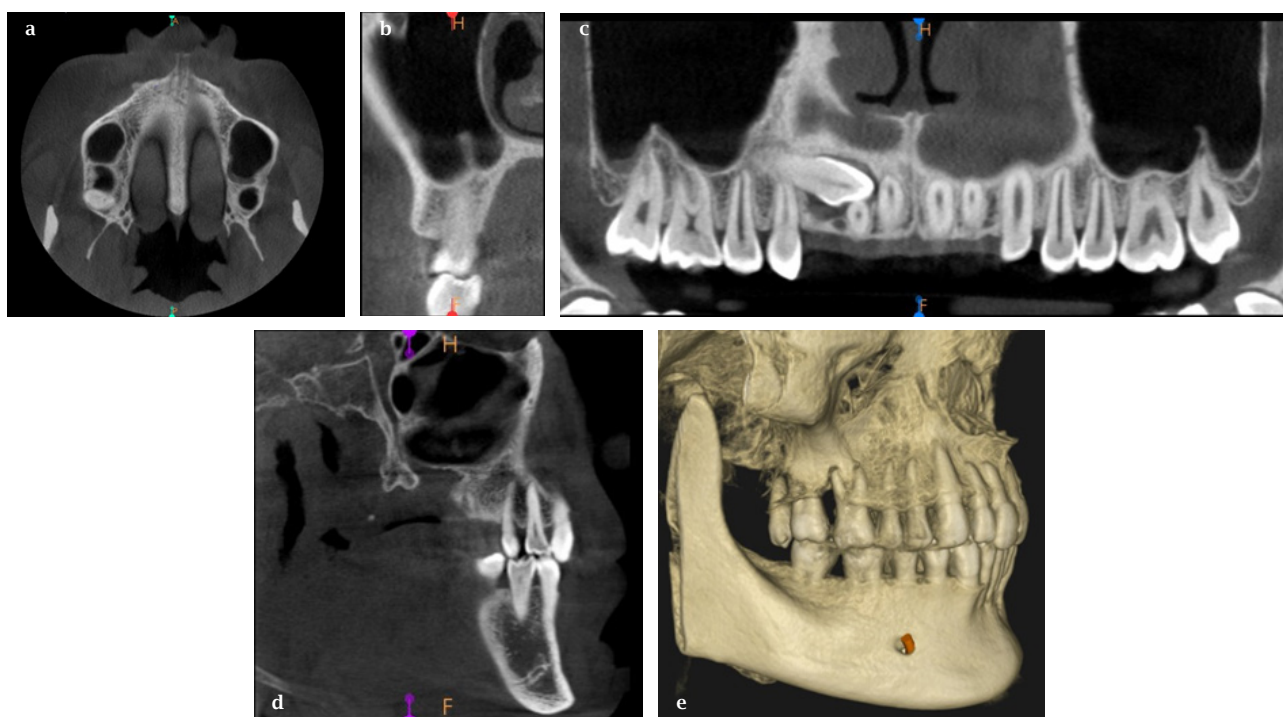


Figure 1: Reconstructed axial (a), cross-sectional (b), panoramic (c), sagittal (d) and 3 dimensional (e) CBCT images used for detection and measurement of maxillary sinus septa.

Table 1: Distribution of sinus septum and its association with gender.

Gender	Septa absent in both sinuses n (%)	Number of maxillary septa in right sinus n (%)	Number of maxillary septa in left sinus n (%)	Number of maxillary septa in both sinuses n (%)	Total n (%)
Male	31 (47.69)	16 (24.61)	10 (15.38)	8 (12.30)	65 (100)
Female	25 (55.55)	7 (15.56)	7 (15.56)	6 (13.33)	45 (100)
Total	56 (50.91)	23 (20.91)	17 (15.45)	14 (12.73)	110 (100)

Table 2: Distribution of sinus septum and its association with maxillary sinusitis.

Sinus Septa	Maxillary Sinusitis				Total n (%)	p Value
	No sinusitis in both sides n (%)	Sinusitis in right sinus n (%)	Sinusitis in left sinus n (%)	Sinusitis in both sinus n (%)		
Septa absent bilaterally	46 (82.15)	4 (7.14)	4 (7.14)	2 (3.57)	56 (100)	0.038
Septa present only in right side	14 (60.87)	2 (8.69)	2 (8.69)	5 (21.75)	23 (100)	
Septa present only in left side	8 (47.06)	-	4 (23.53)	5 (29.41)	17 (100)	
Septa present bilaterally	11 (78.57)	-	1 (7.14)	2 (14.28)	14 (100)	
Total	79 (71.82)	6 (5.45)	11 (10)	14 (12.73)	110 (100)	

Table 3: Distribution of maxillary sinus septum and its association with its location.

Sinus Septa	Location of septum in the maxillary arch				Total n (%)	P value
	Absent n (%)	Anterior n (%)	Middle n (%)	Posterior n (%)		
Septa absent in both sides	56 (100)	-	-	-	56 (100)	0.001
Septa present only in right side	-	3 (13.04)	9 (39.13)	11 (47.82)	23 (100)	
Septa present only in left side	-	3 (17.65)	9 (52.94)	5 (29.41)	17 (100)	
Septa present bilaterally	-	4 (28.57)	8 (57.14)	2 (14.29)	14 (100)	
Total	56 (50.90)	10 (9.09)	26 (23.63)	18 (16.36)	110 (100)	

RESULTS

Of the 110 patients evaluated, 65 (59.09%) of them were male, and 45 (40.90%) of them were female with age ranged between 16 and 75 years. A total of 54 of the 110 subjects examined (49.09%) and 68 out of 220 (30.90%) maxillary sinuses examined had one or more septa. The patients having the presence of septum/septa was found to be greater in number in the right side only (23 out of 110, 20.90%) as compared to the left side only (17 out of 110, 15.45%) as well as bilateral presence (14 out of 110, 12.72%). Location of septum/septa was 10 (9.09%) in anterior, 24 (21.82%) in middle and 18 (16.36%) in posterior regions. Male subjects had more prevalence of maxillary septa 34 (62.96%) in comparison with female subjects 20 (37.04%) (Table 1).

Maxillary sinus disease was present in 44 subjects (40%), out of which 31 subjects (28.18%) had sinusitis and 13 (11.82%) had mucosal thickening. Maxillary sinusitis involving both sinuses were present in 14 patients (12.73%), and 6 (5.45%) in right sinus and 11 (10%) in left sinus. In male subjects, 16 out of 54, (29.63%) had more maxillary septum in right sinus, whereas in female subjects, the number of sinus

septum was found to be almost equal in right, left and both sinuses (Table 1).

Regarding association between sinus septa and sinusitis, a greater number of patients with septa had the presence of sinusitis. Ten out of 56 (17.85%) who had no septa had sinusitis. Only 21 out of 54 (49.09%) who had septa had sinusitis, which is statistically significant ($P=0.038$, Table 2).

A statistically significant association was noted between presence of septum and its location, 24 out 54, (44.44%) of septum present in middle region compared to 18 (33.33%) in the posterior and 10 (18.52%) in the anterior region. ($P=0.001$, Table 3).

DISCUSSION

Extraction of tooth results in alveolar bone height reduction due to resorption, which causes difficulty in the placement of dental implants. In such areas, bone graft surgeries need to be done to place dental implants as short or extra short implants might not always serve the purpose for a long term success. Along with bone augmentation, posterior region of maxilla may need surgical procedures like direct

and indirect sinus lift to elevate maxillary sinus floor. These surgeries are very sophisticated and may result in the rupture of the sinus membrane which may interfere with the physiology of the maxillary sinus. Furthermore, other anatomic characteristics, such as the presence of sinus septa may make this surgical technique even more complicated and results in the development of acute or chronic sinusitis and graft resorptions.⁵

A rate of 22.8% sinus membrane perforations occurred, in the study done by Irinakis et al.,⁶ irrespective of whether there was a septum interfering in the region. Interference of septa in maxillary sinuses showed incidence of membrane perforation as 44.7%, with large perforations occurring in 26.3% and small perforations in 18.4% of the cases.

The prevalence of septa in the maxillary sinus ranged between 7% and 70% that used very different imaging techniques like panoramic radiography, conventional computed tomography and CBCT.⁸⁻¹¹ In the present study, sinus septa were observed in 49.1% of the patients evaluated and 30.9% of the total sinuses had septa. Similar results were observed in other studies.¹⁴⁻¹⁷ However higher prevalence of maxillary sinus septa were reported by Zyl et al.¹⁸ with the prevalence of 69% and lower prevalence of 9% were reported by a study done by Yang et al.¹⁹ In the present study, the prevalence of septum is more in right side which is about 20.9%, which is similar to the finding of Koymen et al.²⁰ but it is higher on left side by a study done by Orhan et al.¹² and equal on right and left sinuses by a study done by Shen et al.²¹

In this study, there was no statistically significant association between gender and the presence of septa and its distribution. Other studies, however, showed that males had much more prevalence of sinus septa than females.^{12,18,21,22} The association was noted between sinusitis and the presence of septa and its distribution in the present study which was 54 (49.09%) who had septa had sinusitis which is statistically significant, this was inconsistent with a study done by Zhu et al.,²³ and they have significant association between the absence of sinus septa and sinusitis. In another study, maxillary sinusitis was common in the presence

of complete or incomplete sinus septa,²⁴ and this might be due to larger septa impeding proper drainage of the sinus. However further studies have to be done in larger populations to assess relationship between sinus septum and maxillary sinusitis. Statistically significant association was also noted between the presence of septum and the location in the arch with higher prevalence in the middle region of the maxillary sinus which is also seen in the majority of other studies in the literature.^{6,8,12,25} In the present study, of the total 54 sinuses where septa was present, only one septum was observed whereas Lee et al.²⁶ observed 24.5% of sinuses with one septum, 0.3% with two and Lee et al.²⁷ observed 28% of sinuses with one septum, 5% with two and 1% with three septa.

The high rate of prevalence of sinus septum in this study could be due to the accurate imaging technique, CBCT, as it represents one of the best techniques to evaluate the relevant anatomic variations for the cases of maxillary sinus surgeries.

CONCLUSION

Maxillary sinus septum in the present study was evaluated and was present in almost half of the subjects evaluated, the majorities were unilateral. Evaluation of maxillary sinus septum with the use of appropriate radiographic techniques is necessary to prevent possible complications during sinus surgery. Cone beam computed tomography is a powerful technique for the examination of maxillary sinus which represents three-dimensional representation of the region with minimum radiation. Presence and distribution of maxillary sinus septa is important in planning sinus surgeries and placement of implant in maxillary posterior region.

ACKNOWLEDGEMENT

The authors would like to thank Dr. Sujita Shrestha and Dr. Sunita Khanal, Department of Community and Public Health Dentistry, Kantipur Dental College for assistance in statistical analysis.

Conflict of Interest: None.

REFERENCES

1. Esfahrood ZR, Ahmadi L, Karami E, Asghari S. Short dental implants in the posterior maxilla: a review of the literature. *J Korean Assoc Oral Maxillofac Surg*. 2017 Apr;43(2):70-6.
2. Anduze-Acher G, Brochery B, Felizardo R, Valentini P, Katsahian S, Bouchard P. Change in sinus membrane dimension following sinus floor elevation: a retrospective cohort study. *Clin Oral Implants Res*. 2013 Oct;24(10):1123-9.
3. Cawood JI, Howell RA. A classification of the edentulous jaws. *Int J Oral Maxillofac Surg* 1988;17:232-6.
4. Vinter I, Krmpotic-Nemanic J, Hat J, Jalsovec D. Does the alveolar process of the maxilla always disappear after tooth loss? *Laryngorhinootologie* 1993;72:605-7.
5. Schwarz L, Schiebel V, Hof M, Ulm C, Watzek G, Pommer B. Risk factors of membrane perforation and postoperative complications in sinus floor elevation surgery: review of 407 augmentation procedures. *J Oral Maxillofac Surg*. 2015 Jul;73(7):1275-82.

6. Irinakis T, Dabuleanu V, Aldahlawi S. Complications during maxillary sinus augmentation associated with interfering septa: a new classification of septa. *Open Dent J*. 2017 Mar 22;11:140-150.
7. Lang AC, Schulze RK. Detection accuracy of maxillary sinus floor septa in panoramic radiographs using CBCT as gold standard: a multi-observer receiver operating characteristic (ROC) study. *Clin Oral Investig*. 2019 Jan;23(1):99-105.
8. Pommer B, Ulm C, Lorenzoni M, Palmer R, Watzek G, Zechner W. Prevalence, location and morphology of maxillary sinus septa: systematic review and meta-analysis. *J Clin Periodontol*. 2012 Aug;39(8):769-73.
9. Gandhi KR, Wabale RN, Siddiqui AU, Farooqui MS. The incidence and morphology of maxillary sinus septa in dentate and edentulous maxillae: a cadaveric study with a brief review of the literature. *J Korean Assoc Oral Maxillofac Surg*. 2015 Feb;41(1):30-6.
10. Sakhdari S, Panjnoush M, Eyvazlou A, Niktash A. Determination of the prevalence, height, and location of the maxillary sinus septa using cone beam computed tomography. *Implant Dent*. 2016 Jun;25(3):335-40.
11. Zhang YQ, Yan XB, Meng Y, Zhao YN, Liu DG. Morphologic analysis of maxillary sinus floor and its correlation to molar roots using cone beam computed tomography. *Chin J Dent Res*. 2019;22(1):29-36.
12. Orhan K, Kusakci Seker B, Aksoy S, Bayindir H, Berberoğlu A, Seker E. Cone Beam CT evaluation of maxillary sinus septa prevalence, height, location and morphology in children and an adult population. *Med Princ Pract*. 2013;22(1):47-53.
13. Toraman-Alkurt M, Peker I, Degerli S, Cebeci ARI, Sadik E. Comparison of cone-beam computed tomography and panoramic radiographs in detecting maxillary sinus septa. *J Istanbul Univ Fac Dent*. 2016 Oct 1;50(3):8-14.
14. Park YB, Jeon HS, Shim JS, Lee KW, Moon HS. Analysis of the anatomy of the maxillary sinus septum using 3-dimensional computed tomography. *J Oral Maxillofac Surg*. 2011;69(4):1070-8.
15. Von Arx T, Fodich I, Bornstein MM, Jensen SS. Perforation of the sinus membrane during sinus floor elevation: a retrospective study of frequency and possible risk factors. *Int J Oral Maxillofac Implants*. 2014;29(3):718-26.
16. Li J, Zhou ZX, Yuan ZY, Yuan H, Sun C, Chen N. An anatomical study of maxillary sinus septum of Han population in Jiangsu region using cone-beam CT. *Shanghai Kou Qiang Yi Xue*. 2013;22(1):52-7.
17. Lana JP, Carneiro PM, Machado Vde C, de Souza PE, Manzi FR, Horta MC. Anatomic variations and lesions of the maxillary sinus detected in cone beam computed tomography for dental implants. *Clin Oral Implants Res*. 2012;23(12):1398-403.
18. van Zyl AW, van Heerden WF. A retrospective analysis of maxillary sinus septa on reformatted computerised tomography scans. *Clin Oral Implants Res*. 2009;20(12):1398-401.
19. Yang HM, Bae HE, Won SY, Hu KS, Song WC, Paik DJ, et al. The buccofacial wall of maxillary sinus: an anatomical consideration for sinus augmentation. *Clin Implant Dent Relat Res*. 2009;11 Suppl 1:e2-6.
20. Koymen R, Gocmen-Mas N, Karacayli U, Ortakoglu K, Ozen T, Yazici AC. Anatomic evaluation of maxillary sinus septa: surgery and radiology. *Clin Anat*. 2009;22(5):563-70.
21. Shen EC, Fu E, Chiu TJ, Chang V, Chiang CY, Tu HP. Prevalence and location of maxillary sinus septa in the Taiwanese population and relationship to the absence of molars. *Clin Oral Implants Res*. 2012;23(6):741-5.
22. Kim MJ, Jung UW, Kim CS, Kim KD, Choi SH, Kim CK, et al. Maxillary sinus septa: prevalence, height, location, and morphology. A reformatted computed tomography scan analysis. *J Periodontol*. 2006;77(5):87903-8.
23. Zhu L, Wu HB, Fang GL, Wang L, Yuan HS, Yan Y, et al. [Significance of maxillary septa in endoscopic nasal surgery]. *Zhonghua Er Bi Yan Hou Tou Jing Wai Ke Za Zhi*. 2010;45(1):24-7.
24. Balasubramanian thiagarajan. Role of imaging in rhinology. 1st edition. Dec. 2014, page 111.
25. Şimşek Kaya G, Daltaban Ö, Kaya M, Kocabalkan B, Sindel A, Akdağ M. The potential clinical relevance of anatomical structures and variations of the maxillary sinus for planned sinus floor elevation procedures: a retrospective cone beam computed tomography study. *Clin Implant Dent Relat Res*. 2019 Feb;21(1):114-21.
26. Lee W-J, Lee S-J, Kim H-S. Analysis of location and prevalence of maxillary sinus septa. *J Periodontal Implant Sci*. 2010 Apr;40(2):56-60.
27. Lee HW, Lin WS, Morton D. A retrospective study of complications associated with 100 consecutive maxillary sinus augmentations via the lateral window approach. *Int J Oral Maxillofac Implants*. 2013 May-Jun;28(3):860-8.