

An Interdisciplinary Approach for Rehabilitation of a Patient with Amelogenesis Imperfecta: A Case Report

Dr. Soni Bista,¹ Dr. Khushbu Adhikari,² Dr. Bikash Kumar Baniya,³ Dr. Suraksha Subedi,¹
Dr. Amrita Pandey,⁴ Dr. Reecha Bhadel⁵

¹Department of Periodontology and Oral Implantology, College of Dental Surgery,
Gandaki Medical College, Pokhara, Kaski, Nepal;

²Department of Periodontology and Oral Implantology, College of Dental Surgery,
B.P. Koirala Institute of Health Sciences, Dharan, Sunsari, Nepal;

³Department of Periodontology and Oral Implantology, College of Dental Surgery,
Universal College of Medical Sciences, Siddharthanagar, Rupandehi, Nepal;

⁴Department of Prosthodontics and Maxillofacial Prosthetics, College of Dental Surgery,
National Medical College, Birgunj, Parsa, Nepal;

⁵Department of Prosthodontics and Maxillofacial Prosthetics, College of Dental Surgery,
Universal College of Medical Sciences, Siddharthanagar, Rupandehi, Nepal.

ABSTRACT

An interdisciplinary approach can be used to treat the uncommon hereditary defect known as amelogenesis imperfecta, which is characterised by insufficient crown length, hypersensitivity, dental caries, and decreased vertical dimension. The present case report describes a successfully managed case of amelogenesis imperfecta with full mouth rehabilitation using implant supported prosthesis. This interdisciplinary approach helped to restore the function and aesthetic of an adult patient, which was followed up for six years without any complications.

Keywords: Aesthetics; amelogenesis imperfecta; dental implant; interdisciplinary approach; tooth sensitivity.

INTRODUCTION

Amelogenesis imperfecta (AI) is an uncommon inherited disorder that affects both the primary and permanent teeth and results in inadequate enamel formation or calcification.¹ Its prevalence is estimated to be between 1:1700 and 1:14000 worldwide,² but is only 0.33% in Nepal.³ AI can be divided into four categories: hypoplastic, hypomaturation, hypocalcification, and hypomaturation-hypoplasia.⁴

The problems confronted by such patients are impaired aesthetics, hypersensitivity, caries, and decreased occlusal vertical dimension, which entail therapeutic approaches from different specialties.¹ The present clinical report describes the rehabilitation of an adult

patient presenting with AI through an interdisciplinary approach.

CASE REPORT

A 42-year-old male patient reported to the Department of Periodontics of the Universal College of Medical Sciences, Siddharthanagar, Rupandehi, Nepal, with chief complaints of tooth discoloration and sensitivity for the past five years. Intraoral examination revealed grossly decayed posteriors and missing teeth in relation to teeth: #26, #27, #28, #37, #36, #35, #42, #43, and #44 (according to two-digit tooth numbering system). Furthermore, generalised attrition, brownish discoloration and bleeding on probing were observed. Additional findings included square-shaped, rougher surfaces with diffused pitting and cracked lines, as well as generalised small-sized crowns (Figure 1). Radiographic examination with orthopantomogram revealed generalised thinning of enamel and root canal treated #21, #22, and #23 (Figure 2). In order to rule out any features related to brittle bone disease, patient was advised for orthopaedic consultation but such features were not perceived.

Correspondence

Dr. Soni Bista

Email: sonibista12345@gmail.com



Citation

Bista S, Adhikari K, Baniya BK, Subedi S, Pandey A, Bhadel R. An Interdisciplinary Approach for Rehabilitation of a Patient with Amelogenesis Imperfecta: A Case Report. J Nepal Soc Perio Oral Implantol. 2022 Jul-Dec;6(12):98-102.

This is an open access journal, and articles are distributed under the terms of the Creative Commons Attribution CC BY 4.0 Licence.

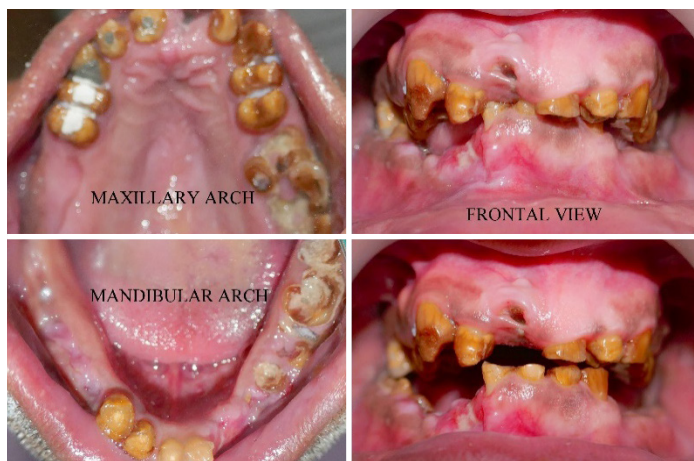


Figure 1: Preoperative clinical view.

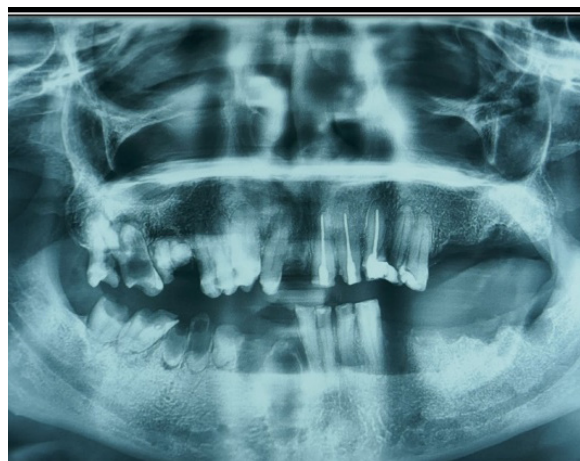

Figure 2: Preoperative radiographic view.

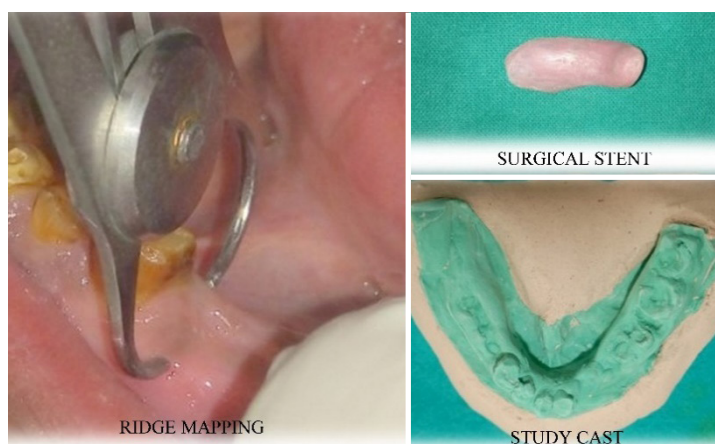


Figure 3: Pre-evaluation done clinically.

Based on the clinical and radiographic findings, the patient was diagnosed with hypoplastic amelogenesis imperfecta with chronic generalised marginal gingivitis. Based on his desire to restore the aesthetic and function of the dentition, a full mouth rehabilitation was planned involving the department of periodontics, oral surgery, endodontics, and prosthodontics. The entire treatment plan was explained to the patient, and informed consent was obtained. A complete haemogram was advised, which depicted values within normal limits. Diagnostic impressions and study casts were prepared, and ridge mapping was done to determine the size of the implant (Figure 3). Initially, the patient underwent scaling and root planing with oral hygiene instructions. The patient was advised to have hopeless teeth extracted (#18, #17, #16, #11, #34, #45, #46, and #47) and root canal treatment for all remaining teeth. Furthermore, implant surgery for replacement of missing teeth followed by insertion of fixed prosthesis was planned.

After a month, surgical therapy was scheduled. The patient was instructed to use a 0.2% chlorhexidine mouth rinse prior to surgery. Left inferior alveolar and

long buccal nerve block was administered using 0.2% Lignocaine with adrenaline. A crestal incision extending from #34 to #36 tooth regions was given with the help of #15 surgical blade, followed by reflection of the mucoperiosteal flap using Molt's #9 periosteal elevator (Figure 4a). Osteotomy site preparation in relation to 34 was carried out initially with a Tri-step drill at a speed of 800 rpm, along with saline irrigation. Further, the preparation was followed by pilot drills with a diameter of 2.8 mm and 3.5 mm in a sequential manner (Figure 4b). An implant depth gauge and parallel pin were used to ensure the depth and angulation for implant placement (Figure 4c). In regard to #34, the ADIN Touareg Close Fit™ Dental Implant (AFULA, Israel) sized 3.75 mm x 13 mm was inserted. Torque was applied using a hand wrench at a rate of 35 N/cm. Simultaneously, the osteotomy site was prepared at #36, and implant of size 5*10 mm² was inserted. After the insertion, cover screws were secured, and the sites were thoroughly irrigated. In addition, flaps were approximated, sutured with 4-0 silk sutures using the interrupted loop suturing technique (Figure 4d). Then, the operated site was protected using periodontal dressing (COE-PAK™ GC America).

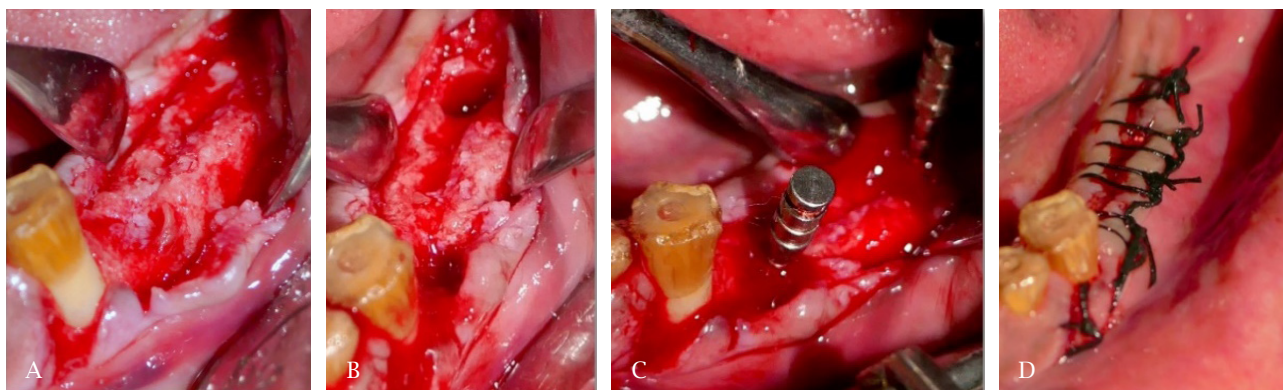


Figure 4: A) Full thickness flap reflection with exposure of alveolar ridge of the third quadrant. B) Osteotomy sites were prepared in relation to #34 and #36. C) Parallel pins placed within osteotomy sites. D) Interrupted loop suturing done.

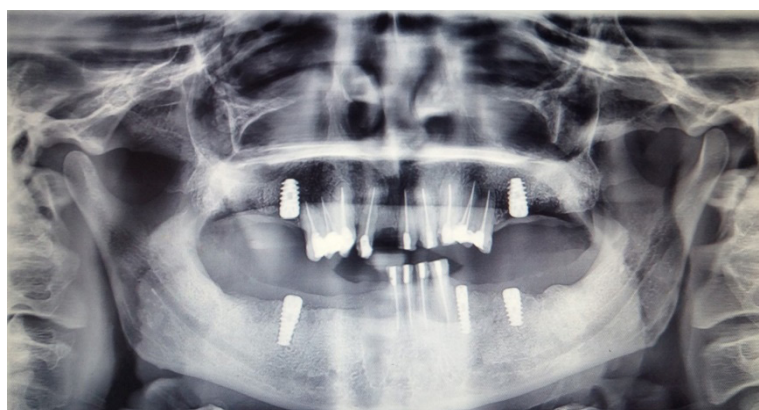


Figure 5: Post-operative radiographic view after three months showing implants placed in relation to #16, #26, #36, #34, and #46.

The patient was prescribed capsule amoxicillin with a dosage of 500 mg three times daily for a week and tablet ibuprofen 400 mg three times daily for three days. Chlorhexidine mouth rinse 0.2% (10 mL) was also prescribed twice daily for two weeks. Periodontal dressing and suture removal were done two weeks post-operatively. Likewise, implant placement was completed sequentially in relation to #16, #26, #42, #44, and #46 at a two-week gap for each quadrant (Figure 5). During the maintenance phase, satisfactory healing was observed.

After four months, the patient was recalled. The implants were exposed, and cover screws were replaced with

healing caps sequentially for all the sites. Simultaneously, surgical crown lengthening with gingivectomy was performed in the upper and lower anteriors (Figure 6). The patient then underwent the restorative phase where he was sent to the department of prosthodontics for full-mouth rehabilitation with the fixed prosthesis. The final insertion of a porcelain-fused metal bridge for the posterior teeth and zirconia crowns in the anterior teeth was completed (Figure 7). The patient was followed up at regular intervals of six months for six years, where the clinical and radiographic examination revealed stable, healthy periimplant soft tissue with osseointegration (Figure 8a and 8b).

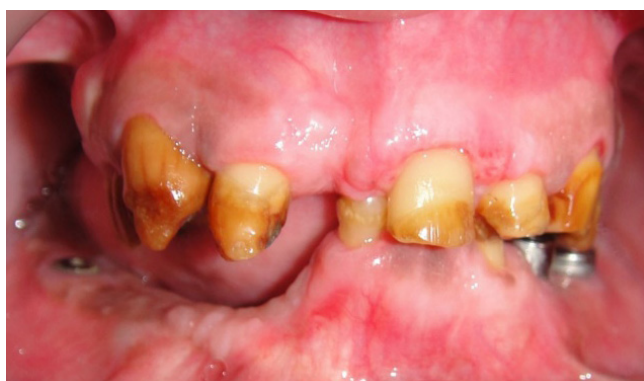

Figure 6: Surgical crown lengthening done.

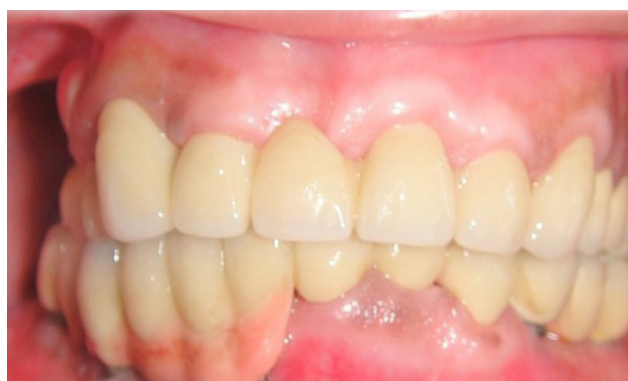

Figure 7: Post-operative clinical view after placement of implant supported fixed prosthesis.

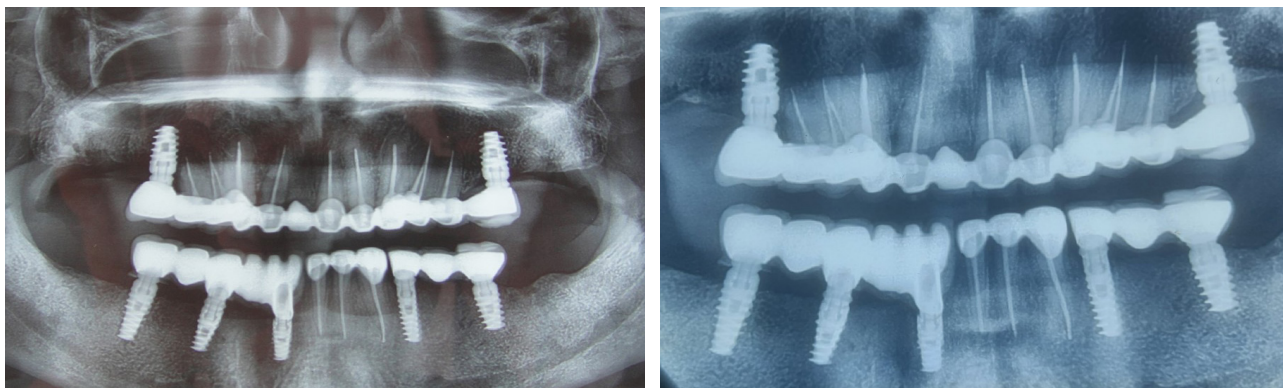


Figure 8: A) Post-operative radiographic view after one year of full mouth rehabilitation. B) Post-operative radiographic view after six years of full mouth rehabilitation.

DISCUSSION

Patients with AI often experience impaired aesthetics and problems in mastication, leading to early tooth loss.⁵ Various treatment modalities can be opted by such patients to optimise the longevity, such as orthognathic surgery, prosthetic crowns, veneers, etc. For the replacement of missing teeth, dental implants provide promising treatment alternatives. The alveolar ridge and neighboring natural tooth structure are preserved.⁶ The restrictions include a lack of accessible space, a thin enough alveolar ridge, and insufficient alveolar bone support for the gingival papilla.⁷ Implant surgery to replace missing teeth was planned for our patient, followed by the insertion of a fixed prosthesis. Therefore, a multidisciplinary strategy requiring the roles of a prosthodontist, maxillofacial surgeon, endodontist, and periodontist was required for long-term success in the present case. Other clinicians also successfully applied this strategy.^{1,5}

In patients with AI, Ameri et al.⁸ recommended extractions of all unrestorable teeth and rehabilitation with implant-supported prosthesis as the most effective choice, which was also carried out in the present case. Previous literature revealed that fixed implant-supported prosthesis achieved high cumulative survival rates.⁹ Full mouth rehabilitation was done with zirconia crowns in the anterior segment to restore the patient's esthetic and porcelain fused to metal crowns in the remaining posterior teeth. The benefit of using a zirconia crown has been evidenced in various studies as its low weight reduces the gravity-induced loading stress.⁸

In addition, crown lengthening was performed in anterior teeth in the patient to increase the extent of supragingival tooth structure and to allow a healthy, optimal relationship between the restoration and the periodontium. It is also a viable option for improving aesthetics, as suggested by previous report.¹⁰ As a result, clinicians must consider treatment options that balance the aesthetics and functional needs of the patient for their overall well-being and long-term prognosis.

SUMMARY

Complete rehabilitation of an AI patient is a constant challenge to the clinician which necessitate an interdisciplinary approach with active involvement of various branches of dentistry. This approach should be oriented towards sustaining the functional, aesthetic and physical well-being of the patient.

ACKNOWLEDGEMENT

The authors would like to acknowledge and thank Dr. Devendra Mandhyan from the Department of Prosthodontics and Maxillofacial Prosthetics for his insightful advice regarding the management of the present case. Additionally, the authors would also like to acknowledge the patient for his good compliance and cooperation during the treatment.

Conflict of interest: None.

REFERENCES

1. Arshad M, Shirani G, Mahgoli HA, Vaziri N. Rehabilitation of a patient with amelogenesis imperfecta and severe open bite: A multidisciplinary approach. *Clin Case Rep.* 2019;7(2):275-83.
 2. Sundell S, Koch G. Hereditary amelogenesis imperfecta. I. Epidemiology and clinical classification in a Swedish child population. *Swed Dent J.* 1985;9(4):157-69.
 3. Gupta SP, Rauniyar S. Prevalence and distribution of dental anomalies among orthodontic patients of Kathmandu, Nepal. *Orthodontic Journal of Nepal.* 2019;9(2):23-8.
 4. Witkop CJ Jr, Kuhlman W, Sauk J. Autosomal recessive pigmented hypomaturation amelogenesis imperfecta. *Oral Surg Oral Med Oral Path Oral Radiol.* 1973;36(3):367-82.
 5. Ramos AL, Pascotto RC, Filho LI, Hayacibara RM, Boselli G. Interdisciplinary treatment for a patient with open-bite malocclusion and amelogenesis imperfecta. *Am J Orthod Dentofacial Orthop.* 2011;139:S145-53.
 6. Valle AL, Lorenzoni FC, Martins LM, Valle CV, Henriques JF, Almeida AL, et al. A multidisciplinary approach for the management of hypodontia: Case report. *J Appl Oral Sci.* 2011;19(5):544-8.
 7. Bishop K, Addy L, Knox J. Modern restorative management of patients with congenitally missing teeth: 4. The role of implants. *Dent Update.* 2017;34(2):79-80, 82-4.
 8. Ameri N, Alikhasi M, Rezayani V. Full mouth rehabilitation with retrievable metal-ceramic implant-supported fixed prostheses for a young patient with atrophic jaws: A clinical report. *Clin Case Rep.* 2017;5(9):1531-5.
 9. Malo P, Nobre A de M, Lopes A, Moss SM, Molina GJ. A longitudinal study of the survival of All-on-4 implants in the mandible with up to 10 years of follow-up. *J Am Dent Assoc.* 2011;142(3):310-20.
 10. Khodaeian N, Sabouhi M, Ataei E. An interdisciplinary approach for rehabilitating a patient with amelogenesis imperfecta: A case report. *Case Rep Dent.* 2012;2012:432108.
-