

Clinical Profile and Treatment Outcome of Patients with Trigeminal Neuralgia: A Retrospective study in a Tertiary Hospital of Eastern Nepal

Dr. Iccha Kumar Maharjan,¹ Dr. Jyotsna Rimal,¹ Dr. Asish Subedi,² Dr. Pragya Regmee¹

¹Department of Oral Medicine and Radiology, College of Dental Surgery, B.P. Koirala Institute of Health Sciences, Dharan, Sunsari, Nepal;

²Department of Anaesthesia and Critical Care, B.P. Koirala Institute of Health Sciences, Dharan, Sunsari, Nepal.

ABSTRACT

Introduction: Neuropathic orofacial pain is common non-dontogenic pain. Diagnosis relies primarily on history taking with less of pathologic change visible. Trigeminal neuralgia (TGN) is a common neuropathic pain affecting the maxillofacial region of fifth cranial nerve (V).

Objective: To assess clinical characteristics, effective therapeutic regimen, side effect, radiographic and laboratory investigation in Trigeminal neuralgia patients.

Methods: Retrospective study included all patients visiting the department with records from 2014 to 2021. After ethical approval for study, eighty patients were diagnosed based on ICHD3 criteria. Patient with atypical feature with sensory deficit underwent CT OR MRI to rule of mass or lesion along the cerebello-pontine angle recess and other organic cause. The data were analysed using SPSS version 11.5 and Microsoft Excel 2017.

Results: A total of 80 patients were retrieved. The common side affected were right 46 (57.5%) followed by left 28 (35%), bilateral four (5%) and anterior region two (2.5%). The most common branch involved was mandibular followed by maxillary branch and combination. Management was primarily done by carbamazepine (CBZ) or in combination. Common side effects were drowsiness, dizziness, nausea and diplopia. CT scan and MRI showed space occupying lesion in three cases. Refractory cases underwent neurolysis and symptomatic and few classical TGN cases were sent for surgical management.

Conclusions: Diagnosis of Trigeminal neuralgia is primarily based on clinical characteristic due to high cost and unavailability of imaging and nerve testing. Treatment is by single or multiple drugs with adjunct therapy.

Key words: Carbamazepine; Nepal; Therapeutics; Trigeminal neuralgia;

INTRODUCTION

Orofacial pain is one of the most common cause for a patient to visit a dental hospital. Neuropathic pain is one of the causes, whose diagnosis relies primarily on history taking as there is less of pathologic change seen clinically. Trigeminal neuralgia (TN) or Fothergill's disease has been described as among the most painful orofacial pain of neuropathic origin. It is most common intermittent neuropathic pain affecting trigeminal nerve (V).¹⁻⁴ The annual incidence of TN is 4 to 5/ 100,000.³ TN

affects one or more sensory branches of the trigeminal nerve, mostly the second or third division.^{4,6} Three clinical types as per ICHD-3 are- classic, idiopathic and symptomatic. Etiology are either idiopathic or vascular compression or tumors, multiple sclerosis (MS) and structural abnormalities of the skull base.⁷⁻⁹ The objective of the study was to describe the clinical characteristics, effective treatment regimen and side effects in Trigeminal neuralgia patients. On extensive literature review there were few case series and case report from Nepal and hence the study was planned.⁹

Correspondence

Dr. Iccha Kumar Maharjan

Email: mailingiccha@gmail.com

Citation

Maharjan IK, Rimal J, Subedi A, Regmee P. Clinical Profile and Treatment Outcome of Patients with Trigeminal Neuralgia: A Retrospective Study in a Tertiary Hospital of Eastern Nepal. *J Nepal Soc Perio Oral Implantol.* 2022 Jul-Dec;6(12):85-90.



METHODS

The study was conducted after ethical approval from the institutional review committee of B.P Koirala Institute of Health Sciences (Ref. IRC/2170/021). This retrospective chart review included all patient visiting the Department of Oral Medicine and Radiology from

This is an open access journal, and articles are distributed under the terms of the Creative Commons Attribution CC BY 4.0 Licence.

January 2014-October 2021. A proforma including detailed history on demographics, branch of nerve, severity using numeric rating scale (NRS), trigger zone, clinical types, radiographic and laboratory investigation, single or combination of medical therapy, physiotherapy, Transcutaneous Electric Nerve Stimulation (TENS), alcohol nerve block and referral for surgical treatment were recorded. Finding of clinical examination of trigeminal nerve including sensory, motor and corneal reflex with oral soft and hard tissue examination, pulp vitality testing and panoramic imaging done to rule out somatic cause were recorded. Patients with refractory or secondary feature with no corneal reflex and sensory deficient underwent CT or MRI to rule out mass or lesion along the cerebello-pontine angle recess and other organic cause.^{1,2} Patient were diagnosed with trigeminal neuralgia as per International Classification of Headache Disorders, 3rd edition, from the International Headache Society (ICHD-3/IHS)⁴ as: paroxysmal attacks of pain affecting the trigeminal nerve, the pain can be described as sudden, superficial, or stabbing,-the attacks are similar among patients and no neurologic disorder is clinically evident. Deficient data having insufficient clinical recording and patient with unknown response to treatment were excluded. The complete blood count (CBC), liver function tests (LFT), and peripheral blood smear (PBS) and in elderly sodium/potassium were done as baseline investigation and on follow-up were recorded. The medical management done: drugs and its combination used, side effect of drugs, TENS therapy given, alcohol nerve block and neurosurgical

management were recorded. The data were coded and entered in MS excel sheet and exported to SPSS software (version 11.5) for statistical test. The frequencies and percentage, Mean, median and standard deviation (SD) were used for descriptive analysis.

RESULTS

The study included 80 patients who met the inclusion criteria. Sample age range was 23 to 84 years old with mean of 56.13± 13.35 years. Age categorisation: there were 38 (40%) patient below 50 years and 42 (60%) above 50 years. There were 35 (43.2%) male and 45 (56.2%) were female with female to male ratio of 1.28. The common side of face involvement was right 46 (57.5%) followed by left 28 (35%), bilateral four (5%) and anterior region two (2.5%). The duration of pain at the time of diagnosis was three days to 20 years. The most common trigeminal branch involved were mandibular branch 34 (42.5%) was followed by maxillary branch 33 (41.25%) and combination in 13 (16.25%) in which one involved ophthalmic branch. The mean pain severity in numeric rating scale (NRS) was 8.93±1.09, most having severe pain in 77 (96.2%) patients. Trigger zones were more frequently present extraoral in 62% of cases on the face and jaw and subsequently intraoral in 38% in the teeth and alveolus (Figure 1), 19 (23.75%) cases had multiple sites involved intraoral or extraoral or both. The clinical types of trigeminal neuralgia were classical 52 (65.0%), idiopathic 19 (23.8%), and symptomatic nine (11.3%) as in (Table 1).

Table 1: Distribution of frequency of different socio-demographic characteristics.

| | |
|------------------------|---|
| Gender | Male -35 (43.2%) Female- 45 (56.2%); Female to male ratio of 1.28 |
| Age (years) | Range: 23 to 84 years, Mean 56.13± 13.35. |
| Duration months (mean) | 3days to 20 years |
| Side involved | Right- 46(57.5%), left-28 (35%), bilateral 4(5%) and 2 (2.5%) anterior region |
| Branches involved | Mandibular branch 34 (42.5%) Maxillary branch 33 (41.25%) Combination in 13 (16.25%) |
| Pain severity in (NRS) | Mean 8.93±1.09 and severe (>7) in 77 (96.2%) |
| Previous treatment | No treatment-17 (21.25%) Extraction-28 (35%) RCT-8 (10%) Analgesics-17(21.25%) Others-10(12.5%) |

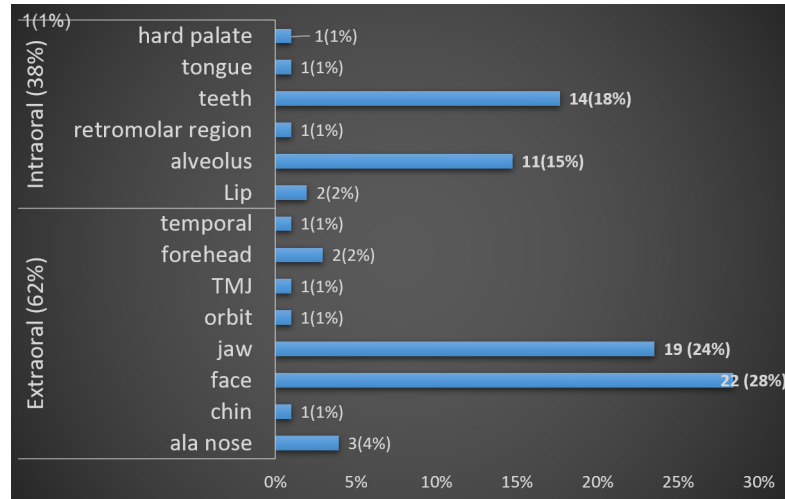


Figure 1: Common intraoral and extraoral trigger zones; face, followed by jaw, teeth, alveolus, ala of nose, forehead, lip, and temporomandibular joint.

Medical management - The different drugs used in medical management of trigeminal neuralgia were carbamazepine (CBZ), baclofen (BCL), pregabalin (PRE), gabapentin (GBN) and lamotrizine (LMZ). Carbamazepine was the first line of therapy if intolerant oxcarbazepine (OXY) was used, if allergic to carbamazepine than gabapentin or baclofen was used. Combination of drug had a benefit of synergistic effect, hence was more effective than single drug (Figure 2). The combination therapy consisted of two drugs regimen and if ineffective three drugs regimen were prescribed. The various combination therapy used were CBZ or OXY with BCL or PRE or GBN and LMZ for two drugs and for third drug added was AMY or nortriptyline (NOR) and acetaminophen or tramadol were added during acute exacerbation. The lowest effective single dose of carbamazepine was 200 mg/day and maximum dose was 1200 mg/day (Figure 2).

Common side effects were seen in 54 (67.5%) patients were: drowsiness, dizziness, nausea, vomiting, diplopia,

drug hypersensitivity, pedal edema and tremors respectively (Table 2). To reduce adverse effect low dose carbamazepine was given multiple times upto three to five times per day or combined with other drugs, topical anesthetics, acetaminophen, opioids and physiotherapy like TENS was used. Carbamazepine hypersensitive patient were given gabapentin or baclofen. Partial relief was reported in 21 (26.3%) patient. Patients with partial pain relief and refractory to drugs were treated using TENS therapy 32 (40 %). Fourteen patients non responsive to medical management or unable to continue the treatment due to adverse effect were referred for neurolysis by absolute alcohol nerve block 14 (17.5%) and likewise non responding along with secondary cases nine (11.5%) were referred for surgical management. The complete blood count, liver function tests and peripheral blood smear were done as baseline investigation for monitoring the side effect of the drugs. Altered LFT was seen in six case with CBZ, they were substituted with OXY or GBN. The CT scan was done in six cases and MRI brain Constructive Interference in Steady State (CISS)

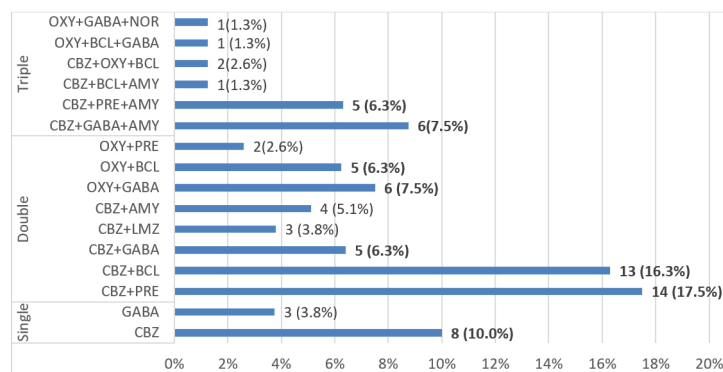


Figure 2: Bar diagram showing different treatment regimen.

Table 2: Different therapeutic regimen and associated drugs side effects.

| | |
|------------------------------|--|
| Medical treatment | Single-11 Combination- 69 |
| Dose of CBZ Dose of OxCBZ | 200-1200mg/day 900-2400 mg/day |
| Drugs side effects | Drowsiness-18 Dizziness-12 Nausea vomiting 6 Diplopia-5 Hypersensitivity-3 Pedal edema-3 Tremors-3 Maniac=1 (BCL) |
| Duration of treatment | 2 months to 22 years |

Classical

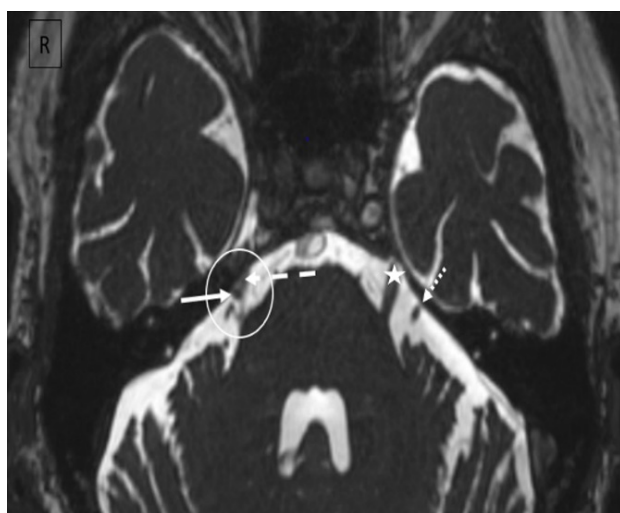

Figure 3: MRI T2 weighted (axial) image.

Idiopathic

Secondary

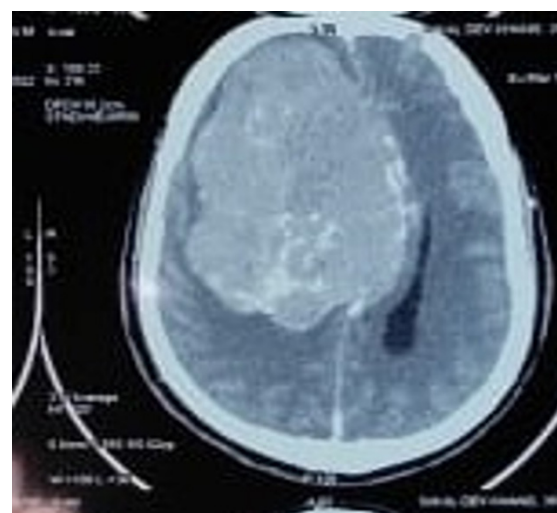

Figure 4: CECT showing large meningioma.

sequence in axial plane was done in 19 cases to rule out space occupying lesion in cerebello-pontine angle and vascular conflict induced demyelination. There were eight (5%) classical cases and three (3.75%) secondary cases (Figure 3, 4)

DISCUSSION

The research included 35 (43.2%) male and 45 (56.2%) female with female to male ratio of 1.28 which is lower than earlier studies showing ratio of 3:1.³ Similar to previous studies women were affected more frequently than men.^{8-11,18} The findings in this study regarding TN are in agreement with most aspects of reports in other population groups.

Age of onset in this study was 56.13±13.35 years with 38 (40%) patient below 50 years and 42 (60%) above 50 years which corresponds well to previous findings with the age of incidence between 50 and 70 years.^{3,10-12,18}

Though, younger age patient in second decades were found to be affected and need a detailed neurological assessment to exclude associated secondary cause. Right side of the face was affected more frequently than the left side can be attributed to narrow foramen rotundum and foramen ovale on right side. This observation is consistent with most reports.^{2,8,10,18,22} In present study, there was no sex difference regarding the side of the face involved. Bilateral involvement was a rare occurrence.^{8,10,18} Five percent of study sample had bilateral involvement which is lower than the incidence of 6.8% reported in Singaporean population by Loh et al.¹⁰ Mandibular branch was the most frequently involved followed by maxillary and ophthalmic as reported by Loh et al. and Jankittivong et al.^{10,18} In contradiction other research reveal the most affected branch to be maxillary division;^{8,13,14,18} Surprisingly, we found higher frequency of combinations of two or three branches and bilateral involvement in 13 (16.25%)

which was higher than the previous studies.^{8,13,18} Branch involved were confirmed by giving the respective nerve block, supratrochlear nerve block caused pain relief in 1 patient. Bilateral or multiple branches of cranial nerve involvement, sensory deficient and absence of corneal reflex is suspicious for secondary neuralgia study by Bagheri et al.^{1,9,12,23} We observed that overtime; the single branch may involve two or more branches and sometimes the contralateral side. The mean NRS was 8.93 of whom, seventy seven patient had severe pain similar to results in previous studies.^{8-10,13,18} Extraoral and intraoral pain originating from the teeth is common often mimicking tooth pain leading to unnecessary treatment like extraction or RCT by the general dentist, early diagnosis is possible by referral to oral medicine and orofacial pain specialist or neurologist^{10-12,18} All patients in this study were initially treated with drug therapy, usually first with carbamazepine 200 mg and gradually increased to maximum of 1200 mg similar to previous study.^{10,18} American Academy of Neurology and the European Federation of Neurological Societies recommend carbamazepine (CBZ) and oxcarbazepine (OXC) as the first drug of choice in (TN).¹⁰ Carbamazepine was more effective but overtime are found to need higher dose due to self-induction. Oxycarbazepine was used at a substitute or as alternate basis as night dose when side effect developed. Gabapentin was considered as drug of choice when allergic to carbamazepine. Studies show that Oxcarbazepine has equivalent efficacy to carbamazepine and is well tolerated with lesser adverse effects and was used in cases with altered liver function to carbamazepine.²¹ In refractory cases, oxcarbazepine 600- 1800 mg was useful alternative for the treatment of TN as in other studies by Zakrewska et al.^{22,23} Cases with partial response or intolerable adverse effect were treated with combined medications such as carbamazepine with gabapentin 300-1800mg or pregabalin 75- 300mg or baclofen 20-60mg or lamotrigine 25-100mg or amitriptyline 10-25mg etc. ²¹⁻²³ Younger patient unresponsive to gabapentin were given baclofen. Pregabalin has lesser adverse effect and as effective as gabapentin when prescribed in this patient. Lamotrigine was used as second drug when pregabalin, gabapentin and baclofen were ineffective. The third drugs used in combination was amitriptyline and nortriptyline

The common side effect was drowsiness and dizziness to carbamazepine in low to high doses though it gradually decreased, if persistent; they were given in divided low dose upto five times per day or give with oxcarbazepine or combination of drugs. Diplopia dizziness was associated

with gabapentin and were substituted with pregabalin or baclofen or lamotrigine. Delusion and pedal oedema was seen with baclofen in older age and were replaced with gabapentin. Tremors with nortriptyline was seen in one (1.3%) patient and stopped. Three patient had carbamazepine hypersensitivity with one having Steven Johnson Syndrome who tested positive for HLA-B15:02 and managed by stopping the drugs and steroids therapy in peripheral centre. Rescue dose of paracetamol or tramadol or intravenous fentanyl were given during acute exacerbation. Refractory cases where give TENS therapy once daily for 10 days which was effective but the pain reoccurred gradually with time. Absolute alcohol nerve blocks were given in 14 (17.5%) patient who were pain free after local anesthesia given to the nerve affected. The low number of classical type of neuralgia observed in this study could be due to the MRI imaging not being done for all these patients due to financial constraints and unavailability. Limitation of this study was not all excluded patient with classical neuralgia underwent MRI due to unavailability. The outcome of patients referred to other centres due to unavailability of advanced treatment such radiofrequency thermocoagulation and neurosurgery in this centre could not be assessed.

CONCLUSION

Trigeminal neuralgia is mostly seen neuropathic orofacial pain in elderly patients. Pain may originate in the extraoral and intra oral region. History and characteristic pain features is the mainstay of diagnosis due to high cost and unavailability of imaging and nerve testing. Medical management is first line of treatment unless secondary type. Carbamazepine is drug of choice for treatment and if ineffective use of combination two or more of drugs along with physiotherapy, neurolysis and neurosurgery is recommended. Regular monitoring for possible side effects from drugs is mandatory. Delayed and incorrect diagnosis leads to unnecessary dental intervention.

Prospective study on clinical profiling, MRI findings and treatment outcome with larger sample size is recommended. Exploration on surgical outcome procedure in refractory cases including cryotherapy, laser therapy, peripheral neuroectomy, radiofrequency thermocoagulation and microvascular decompression can be assessed. Long term follow-up to find out the effect of single or combination treatment and adjunct on pain and the duration of effectiveness of medical management can be further researched.

ACKNOWLEDGEMENTS

The authors would like to thank Dr. Niraj Regmi (Assistant Professor) of Department of Radiology and Dr. Bhupendra Shah (Assistant Professor) of Department

of Internal Medicine and all the residents of Department of Oral Medicine and Radiology of B.P. Koirala Institute of Health Sciences for their support.

Conflict of interest: None.

REFERENCES

1. Bagheri SC, Farhidvash F, Perciaccante VJ. Diagnosis and treatment of patients with trigeminal neuralgia. *J Am Dent Assoc.* 2004;135(12):1713-7.
2. Okeson JP. Bell's orofacial pains: the clinical management of orofacial pain. Sixth edition, Quintessence Publishing Co, Inc.
3. De Toledo IP, Conti Rêus J, Fernandes M, Luís Porporatti A, Peres MA, Takaschima A, et al. Prevalence of trigeminal neuralgia A systematic review. *J Am Dent Assoc.* 2016;147(7):570-6.
4. Headache classification committee of the international headache society (ihs). The international classification of headache disorders, 3rd edition (beta version). *Cephalalgia.* 2013;33(9):629-808.
5. Merskey H, Bogduk N. Classification of chronic pain. Descriptions of chronic pain syndromes and definitions of pain terms, 2nd ed, IASP Press, Seattle 1994, 59-71.
6. Jensen TS. Anticonvulsants in neuropathic pain: rationale and clinical evidence, *Eur J Pain.* 2002;6:61-8.
7. Love S, Coakham HB. Trigeminal neuralgia: Pathology and pathogenesis. *Brain,* 2001;124:2347-60.
8. Katusic S, Beard CM, Bergstralh E, Kurland LT. Incidence and clinical features of trigeminal neuralgia, rochester, minnesota, 1945-1984. *Ann Neurol* 1990;27:89-95.
9. Sharma GR, Jha RK, Poudel P, Adhikari DR, Bista P. Microvascular decompression for trigeminal neuralgia: Our experiences at bir hospital. *Nep J Neurosci* 2017;14(2):3-7.
10. Loh HS, Ling SY, Shanmuhasantharam P, Zain R, Yeo JF, Khoo SP. Trigeminal neuralgia. A retrospective survey of a sample of patients in singapore and malaysia. *Aust Dent J* 1998;43:188-91.
11. Loeser JD. Tic douloureux. *Pain Res Manag.* 2001;6:156-65.
12. Darlow LA, Brooks ML, Quinn PD. Magnetic resonance imaging in the diagnosis of trigeminal neuralgia. *J Oral Maxillofac Surg.* 1992;50:621-26.
13. Bowsher D. Trigeminal neuralgia: a symptomatic study of 126 successive patients with and without previous interventions. *The Pain Clinic.* 2000;12:93-101.
14. Di Stefano G, La Cesa S, Truini A, Cruccu G. Natural history and outcome of 200 outpatients with classical trigeminal neuralgia treated with carbamazepine or oxcarbazepine in a tertiary centre for neuropathic pain. *J Headache Pain.* 2014;9:15-34.
15. Bendtsen L, Zakrzewska JM, Abbott J, Braschinsky M, Stefano GD, Donnet A, et al. European academy of neurology guideline on trigeminal neuralgia. *Eur J Neurol.* 2019;26:831-49.
16. Sarideechaigul W, Kithuandee A, Siritapetawee M, Butda P, Jorns TP. Profiling of patients presenting with trigeminal neuralgia and outcome of medical management in tertiary care centre. *J Med Assoc Thai.* 2019;102:57-62.
17. Katusic S, Beard CM, Bergstralh E, Kurland LT. Incidence and clinical features of trigeminal neuralgia, rochester, minnesota, 1945-1984. *Ann Neurol.* 1990;27(1):89-95.
18. Jankittivong A, Aneksuk V, Langlais RP. Trigeminal neuralgia: A retrospective study of 188 Thai cases. *Gerodontology.* 2012;29(2):611-7.
19. Ayele BA, Mengesha AT and Zewde YZ. Clinical characteristics and associated factors of trigeminal neuralgia: Experience from addis ababa, ethiopia. *BMC Oral Health.* 2020;20:244-51.
20. Priyanka Debta P, Sarode G, Sarode S, Sahu MP. Natural history of trigeminal neuralgia - A hospital-based retrospective study. *Oral Dis.* 2020;26(3):647-55.
21. Jorns TP, Zakrzewska JM. Evidence-based approach to the medical management of trigeminal neuralgia. *Br J Neurosurg* 2007;21:253-61.
22. Gomez-Arguelles JM, Dorado R, Sepulveda JM et al. Oxcarbazepine monotherapy in carbamazepine unresponsive trigeminal neuralgia. *J Clin Neuro Sci* 2008; 15:516-9.
23. Zakrzewska JM, Patsalos PN. Oxcarbazepine: A new drug in the management of intractable trigeminal neuralgia. *J Neurol Neurosurg Psychiatry.* 1989;52:472-6.
24. Gronseth G, Cruccu G, Alksne J, Argoff C, Brainin M, Burchiel K, et al. Practice parameter: The diagnostic evaluation and treatment of trigeminal neuralgia (an evidence-based review): Report of the quality standards subcommittee of the american academy of neurology and the european federation of neurological societies. *Neurology* 2008;71:1183-90.
25. Harris W. An analysis of 1,433 cases of paroxysmal trigeminal neuralgia (trigeminal tic) and the end-results of gasserian alcohol injection. *Brain.* 1940;63:209-24.